



City Research Online

City, University of London Institutional Repository

Citation: Marien, P., Tops, W., Crols, R., Jonkers, R., De Deyn, P. P. & Verhoeven, J. (2012). Grammar disruption in a patient with Neuro-Sweet syndrome. *Neurocase*, 18(3), pp. 235-247. doi: 10.1080/13554794.2011.588178

This is the accepted version of the paper.

This version of the publication may differ from the final published version.

Permanent repository link: <http://openaccess.city.ac.uk/14198/>

Link to published version: <http://dx.doi.org/10.1080/13554794.2011.588178>

Copyright and reuse: City Research Online aims to make research outputs of City, University of London available to a wider audience. Copyright and Moral Rights remain with the author(s) and/or copyright holders. URLs from City Research Online may be freely distributed and linked to.

City Research Online:

<http://openaccess.city.ac.uk/>

publications@city.ac.uk

GRAMMAR DISRUPTION IN A PATIENT WITH NEURO-SWEET SYNDROME

Authors: Peter Mariën ^{1*}, Wim Tops ², Roel Crols ¹, Roel Jonkers ³, Peter P De Deyn ¹,
and Jo Verhoeven ⁴

¹ Department of Neurology and Memory Clinic, ZNA-Middelheim, Antwerp,
Belgium

² Department of Experimental Psychology, Ghent University, Belgium

³ Department of Linguistics, University of Groningen, The Netherlands

⁴ Department of Language and Communication Science, City University, London, UK

* The first two authors contributed equally to the manuscript

Abbreviated Title: Neuro-Sweet Syndrome

Corresponding author: Prof dr Peter Mariën

ZNA-Middelheim

Department of Neurology

Lindendreef 1

BE-2020 Antwerp

Belgium

Tel: 0032/3/280.31.36

Fax: 0032/3/281.37.48

E-mail: peter.marien5@telenet.be

ABSTRACT

This paper for the first time reports detailed neurolinguistic findings in a patient with Neuro-Sweet syndrome. In this patient the presenting symptoms of central nervous system involvement primarily consisted of a selective grammar deficit restricted to spontaneous speech. On MRI a left prefrontal ischemic stroke (superior part BA 6) and two small subcortical left parietal infarctions were found. Neurolinguistic analyses, however, did not reveal a profile consistent with any observations of agrammatism caused by structural damage to the language areas critically involved in grammatical processing. It is hypothesized that selectively distorted grammar might reflect disruption of the frontosubcortical network involved in language processing. Prefrontal neurobehavioural abnormalities associated with functional disruption of the inferior medial frontal regions as demonstrated by SPECT, additionally suggest that agrammatic symptoms may be linked to a higher-level cognitive disorder following encephalopathic central nervous system involvement.

Key-words: Neuro-Sweet disease, agrammatism, language, cognition, SPECT

1. INTRODUCTION

Sweet syndrome, also known as acute febrile neutrophilic dermatosis, was first described by Robert D. Sweet in 1964. This inflammatory disorder consists of a reactive process with recurrent bouts of reddish-purple nodules and plaques, mainly on the upper limbs, face and neck, together with fever, malaise and peripheral neutrophilia. A diffuse infiltrate predominantly consisting of mature neutrophils in the upper dermis constitutes its main pathological finding. Papillary dermal oedema is typically present as well. Sweet syndrome can be idiopathic or reactive to a previous infection, pregnancy, vaccination, drug exposure or cancer (especially acute myeloid leukaemia) (Cohen, 2007; Hiari & Borland; 2009) and responds very well to treatment with corticosteroids. In a minority of cases, Sweet syndrome can be multisystemic with involvement of other organs than the skin, including eyes, liver, lungs, kidneys, intestines, bone marrow, and aorta.

In 1999, Hisanaga, Hosokawa, Sato, Mochizuki, Itoyama and Iwasaki for the first time described 'Neuro-Sweet Disease' in a 37-year-old Japanese patient as a distinct entity consisting of benign relapsing and remitting aseptic encephal meningitis with mucocutaneous abnormalities of Sweet syndrome. During a follow-up of 5 years, a series of subsequent CT and MRI scans of the brain revealed several episodes of transient signal abnormalities in various subcortical brain regions (white matter and basal ganglia lesions). A skin biopsy specimen of the erythematous plaques showed neutrophilic dermatitis compatible with Sweet syndrome. In addition, Human Leukocyte Antigen (HLA) testing revealed B54, which is typically reported in Japanese patients with Sweet syndrome. Treatment with oral prednisolone was beneficial for both the encephalitis and the mucocutaneous symptoms and the patient recovered from each episode without any residual focal neurological deficit. Since this first description, Neuro-Sweet syndrome has only been documented in fewer than 30

patients in whom the central nervous system was affected (Fukushima, Hineno, Kodaira, Machida, Ishii, et al., 2008; Hisanaga, Iwasaki, & Itoyama, 2005).

The pathophysiological substrate of Neuro-Sweet disease remains to be clarified (Jiro, Kazuyuki, Kenji, Ryo, Takashi, et al., 2007). In a review of 27 cases, Hisanaga et al. (2005) proposed a set of diagnostic criteria for Neuro-Sweet disease. These included: 1) *neurological features* frequently consisting of recurrent encephalitis or meningitis, usually accompanied by fever over 38°C and highly systemic glucocorticoid responsive or sometimes spontaneously remitting; 2) *dermatologic features* consisting of painful or tender, dull red erythematous plaques or nodules on the face, neck, upper limbs, and upper part of the trunk, predominantly neutrophilic infiltration of the dermis, spared epidermis, and absence of leukocytoclastic vasculitis; 3) *other features* which are seen in Behçet disease such as absence of cutaneous vasculitis and thrombosis, and absence of typical uveitis; and 4) *Human Leucocyte Antigen (HLA) association*: HLA-Cw1 or B54 positive, HLA-B51 negative. Criteria 1, 2 and 3 are required for a diagnosis of probable Neuro-Sweet disease. Possible Neuro-Sweet disease is diagnosed when in addition to any neurological manifestation, criteria 2 or 4 are met and one item or more of criterion 3.

In contrast to Neuro-Behçet's disease, which represents a clinically closely related multisystem vascular-inflammatory disorder and which also affects the central nervous system (CNS) in a limited number of patients (Siva & Saip, 2009), behavioural, cognitive and linguistic functions in Neuro-Sweet disease have not been studied in detail. Apart from a few studies such as Hisanaga et al. (1999) in which cognition was only broadly assessed (WAIS-R total IQ) on one single occasion during a follow-up of 5 years and some anecdotal accounts of the patient's cognitive and mental state, there are no studies in which cognitive functions, behavioural symptoms or language were thoroughly investigated. To the best of our knowledge, this paper is the first to report neurolinguistic and (functional) neuroimaging

findings in a patient who primarily showed a range of neurobehavioural abnormalities secondary to Neuro-Sweet disease.

2. CASE HISTORY

Patient EP was a 72-year-old right-handed, native speaker of Dutch with normal developmental milestones and an educational level of 15 years. She was a qualified nurse and had worked for several years in a children's hospital. After she got married, she stayed home to run a household with four children. She divorced at the age of 55 years and was subsequently treated for a short period by a psychiatrist with antidepressant drugs. At the onset of neurological symptoms she lived independently. She only maintained a few social contacts and for unknown reasons she had not been in touch with any of her children or close relatives for several years. Medical history only consisted of arterial hypertension. There was no known history of stroke, dementia, aphasia nor of any language-related difficulties.

Four days after acute onset of total speechlessness, EP was admitted to the hospital. Before admission, she had almost exclusively used gestures and isolated sounds to communicate. At the onset of neurological symptoms she strongly rejected any medical help and refused to go to hospital. On admission she was fully conscious and alert but hardly cooperative. Her medical condition did not seem to bother her much and she displayed childish and even disinhibited behaviour with frequent verbal exclamations and sudden mood swings. Comprehension of oral and written language was normal, but speech production was limited to one-word-utterances. Writing of words and sentences was normal. Except for disrupted prosody (prolonged speech) no serious motor speech abnormalities were found. Bucco-labio-lingual praxis was normal. There was no dysarthria or apraxia of speech. The clinical neurological examination was normal except for a right plantar reflex which was extensor. The physical examination showed multiple subcutaneous hemorrhages on both arms. Blood

pressure was 160/120 mmHg, heart beat 78 per minute and regular. She was afebrile (tympanic temperature 36.6°C)

As shown in figure 1, MRI of the brain carried out 11 days after onset of symptoms showed small, widespread subcortical white matter lesions, bilateral basal ganglia lesions and a larger acute lesion in the left hemisphere located just anteriorly to the precentral gyrus in the superior part of Brodmann's area 6 (BA6) (Figure 1 A-E). In addition to the acute prefrontal lesion, diffusion-weighted imaging (DWI) showed two additional small acute lesions in the white matter of the left parietal lobe (Figure 1 F-J), which were considered to be of vascular origin.

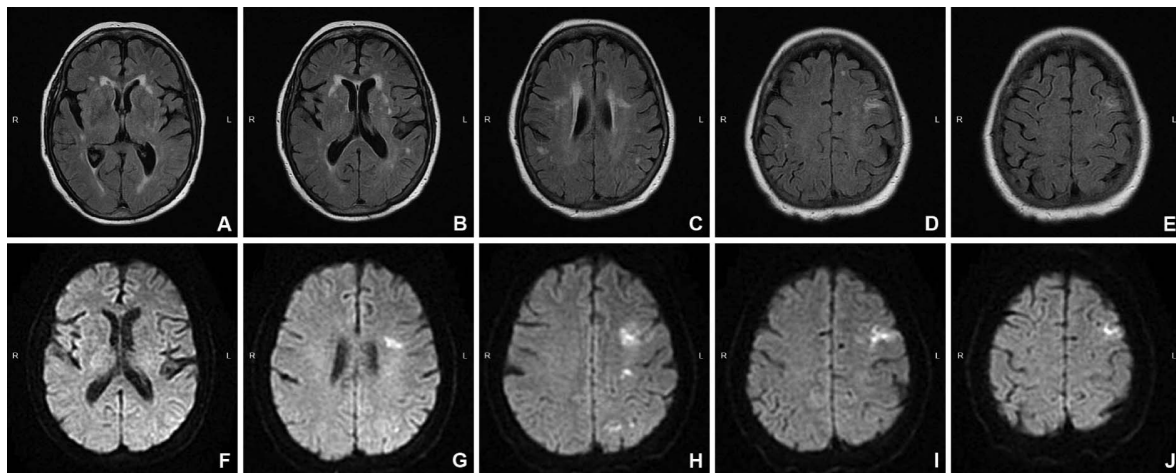


Figure 1. Brain MRI axial FLAIR slices (A–E) 10 days post-stroke disclose widespread small subcortical white matter and basal ganglia lesions and a larger infarction in BA6 (at a depth of 1.5 cm) of the left hemisphere. DWI of the brain (F–J) shows in addition to the acute prefrontal infarction, two additional small acute ischemic lesions in the white matter of the left parietal lobe.

A Tc-99m-ECD SPECT perfusion scan was carried out seven days poststroke using a Trionix (Ohio, USA) Triad three-detector gamma camera equipped with high resolution fan-beam collimators. The projection data were reconstructed by filtered backprojection using a Butterworth filter (with cut-off frequency of 0.7 cyc/cm and rol-off 5) resulting in transaxial images with a pixel size of 3.56 mm. Using a 31 ROI template, Z-scores were calculated for each region. A regional Z-score of >2.0 was considered significant. In comparison to normal

database findings, the study revealed a significant decrease of perfusion bilaterally in the inferior medial frontal regions (left $z = -2.18$; $p < .05$ and right $z = -3.83$; $p < .01$) (Figure 2).

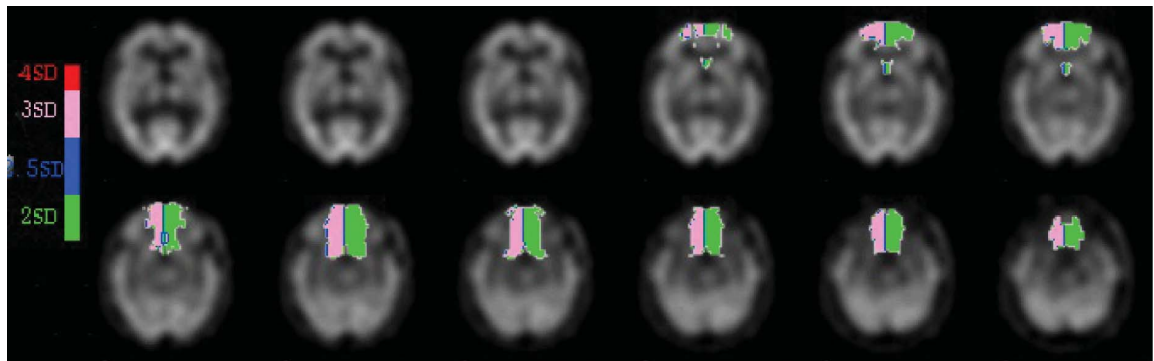


Figure 2. Quantified Tc-99m-ECD SPECT perfusion scan of the brain at 7 days post-stroke demonstrating a significant decrease of perfusion in the left ($z = -2.18$; $p = .02$) and the right ($z = -3.83$; $p = .00$) inferior medial frontal regions.

During her stay in the hospital no cause was found for the acute strokes. Cardiovascular examination, including transesophageal echocardiography and a 24h ECG monitoring, was normal. A duplex of the carotids did not reveal significant stenosis. An elevated sedimentation rate of 86 mm/h suggested vasculitis but ANF, ANCA and serology for syphilis and Lyme disease were negative. Analysis of cerebrospinal fluid, cerebral arteriography and temporal artery biopsy were normal.

One month after her stay in the hospital the patient developed a fever and multiple tender red spots in her face and on her arms. Blood sedimentation was elevated (93 mm/h). The patient reported that she had had recurrent bouts of these spots for a few years. Analysis of a biopsy specimen of a skin lesion indicated Sweet syndrome (acute febrile neutrophilic dermatosis). A diagnosis of Neuro-Sweet syndrome was made and treatment with systemic corticosteroids (methylprednisolone 1mg/kg) was started..

After four months the patient discontinued treatment. At six months and two years post-stroke she consulted the neurological department again upon insistence of her general practitioner. Neurological examination revealed a persistent right Babinski's sign. Speech was normal and no incidences of prosodic or grammatical abnormalities were observed. The

patient, however, refused a control MRI to evaluate the evolution of the lesions. After two years the patient was lost to follow-up.

3. NEUROLINGUISTIC FINDINGS

Formal neurolinguistic investigations were carried out 10 days (acute phase), three months (lesion phase) and two years (late phase) after the stroke. The neurolinguistic test battery consisted of standardised tests which investigate oral and written language modalities at different levels of complexity. The ScreeLing (Doesborgh, Van de Sandt-Koenderman, Dippel, Van Harskamp, Koudstaal, & Visch-Brink, 2003) was used in the acute phase of the stroke to broadly assess expressive and receptive language functions. Auditory and written comprehension of words and sentences were examined in more detail by means of the subtest ‘complex ideational material’ of the Boston Diagnostic Aphasia Examination (BDAE) (Goodglass & Kaplan, 1983), the comprehension subtests of the Aachen Aphasia Test (AAT) (Graetz, De Bleser, & Willmes, 1992) and the Token Test (De Renzi & Vignolo, 1962). Visual confrontation naming was examined by means of the Boston Naming Test (BNT) (Kaplan, Goodglass, & Weintraub, 1983; Mariën, Mampaey, Vervaet, Saerens, & De Deyn, 1998) and the AAT subtests ‘simple nouns’, ‘colour names’, ‘composed nouns’, and ‘sentences’. Language dynamics were formally tested using a semantic verbal fluency task consisting of one minute generation of names of animals, means of transport, vegetables, and clothes (unpublished norms). In-depth investigation of syntactic skills was performed on the basis of the Werkwoorden- en Zinnentest (WEZT) (Bastiaanse, Maas, & Rispen, 2000). Conversational speech was evaluated by means of semi-structured, video-taped interviews (AAT Spontaneous Speech). Written language skills were examined on the basis of the AAT subtests ‘reading aloud’, ‘written comprehension’ (of words and sentences) ‘composing’ and ‘dictational writing’.

In the acute phase of the stroke, general screening of linguistic skills by means of the ScreeLing revealed intact semantic (24/24), phonological (24/24) and syntactic skills (24/24). As demonstrated by the AAT, BDAE and Token Test results (table 1), auditory-verbal and written language comprehension were normal. Repetition of phonemes, morphemes and sentences was normal as well. The naming subtests of the AAT also scored normal. The description of situational pictures was correct. The patient used short but syntactically correct sentences to describe the scenes depicted in the line drawings. The BNT yielded a defective score of 43/60 ($z = -2.3$; $p < .05$). The majority of the mistakes were semantic errors (= 7/17 errors; e.g. crocodile instead of seahorse) and circumlocutions (= 6/17 errors). Subtest results for AAT dictational writing, composition and oral reading were normal. In marked contrast with the patient's normal performance on imposed syntax tasks such as the AAT sentence repetition task, syntax was severely disrupted in spontaneous speech. Oral-verbal output was fluent but almost exclusively consisted of one or two-word-utterances containing nouns or infinitives indicating profound agrammatism. In addition, speech production was disturbed by many exclamations and sighs. Prosody alternated between a plaintive, almost tearful tone and scanned speech. As a result of disrupted prosody and telegrammatic style the patient obtained a pathological score on the AAT sections investigating articulation and prosody ($z = -2.4$; $p < .01$) and syntactic structure ($z = -6.2$; $p < .01$). To examine the agrammatic speech characteristics in more detail, the WEZT was carried out (table 1). Surprisingly, the patient obtained scores that were well within the normal range for all subtests.

Table 1: AAT test results 10 days, 3 months and 2 years post-onset neurological symptoms

Results 10d / 3m / 2yrs	Percentile (Cut-off)	Max	Mean	± 1SD
----------------------------	-------------------------	-----	------	-------

AACHEN APHASIA TEST

Comprehension	112 / 114 / -	96 / 98 / -	120	108.5	10.24
auditory : words	28 / 30 / -	92 / 98 / -	30	26.49	3.30
auditory : sentences	28 / 28 / -	86 / 86 / -	30	26.79	3.41
total	56 / 58 / -	96 / 98 / -	60	53.28	6.08
written : words	30 / 28 / -	95 / 83 / -	30	28.30	2.29
written : sentences	26 / 28 / -	87 / 95 / -	30	26.91	3.39
total	56 / 56 / -	95 / 95 / -	60	55.21	4.90
Token Test (errors)	2 / 2 / 2	98 / 98 / 98	50	2.28	2.75
Spontaneous Speech					
communicative behaviour	4 / 4 / 5	-	5	4.63	0.54
articulation and prosody	3* / 4 / 5	-	5	4.63	0.67
automatisms	5 / 5 / 5	-	5	4.59	0.65
semantic structure	5 / 5 / 5	-	5	4.59	0.53
phonematic structure	5 / 5 / 5	-	5	4.54	0.56
syntactic structure	1* / 2* / 5	-	5	4.41	0.55
Imposed Speech					
total repetition	150 / 150 / -	100 / 100 / -	150	144.1	8.07
phonemes	30 / 30 / -	88 / 88 / -	30	28.91	2.09
monosyllabic words	30 / 30 / -	93 / 93 / -	30	29.22	1.32
loan- & foreign words	30 / 30 / -	95 / 95 / -	30	28.94	2.31
compounds	30 / 30 / 30	98 / 98 / 98	30	28.45	2.22
sentences	30 / 30 / 30	99 / 99 / 99	30	28.55	1.90
total naming	116 / 118 / -	99 / 100 / -	120	109.3	8.42
simple nouns	29 / 28 / -	89 / 81 / -	30	27.92	2.90
colour names	30 / 30 / -	98 / 98 / -	30	27.69	1.99
composed nouns	29 / 30 / -	95 / 99 / -	30	28.04	2.61
sentences	28 / 30 / 30	99 / 100 / 100	30	25.69	3.72
Written Language	90 / 90 / -	100 / 100 / -	90	85.52	7.63
reading aloud	30 / 30 / -	96 / 96 / -	30	28.95	1.93
composing	30 / 30 / -	98 / 98 / -	30	28.57	2.75
dictational writing	30 / 30 / 26	99 / 99 / 83	30	28	3.67
BNT	43* / 51 / -	-	60	52.9	4.25
BDAE	11 / 11 / -	90 / 90 / -	12	-	-
VERBAL FLUENCY	41 / 52 / -	-	-	59.7	13.27
WEZT					
sentence comprehension	40	(39)	40	39.77	0.42
action naming	38	(32)	40	38.77	1.73
completion infinitives	10	(9)	10	9.57	0.5
completion verbs	10	(9)	10	9.65	0.48
sentence construction	20	-	20	16.35	2.95
anagrams with picture	20	(20)	20	20	0
anagrams without picture	20	(20)	20	20	0
Wh- anagrams	19	(18)	20	19.75	0.78

Legend: d = days; m = months; yrs = years; - = data not available; * = significant ($z > 2$)

Three months postonset neurological symptoms (lesion phase), patient's speech was still agrammatic but the telegraphic style had resolved. The patient no longer used one-

word-utterances but overall sentence length remained short. The grammatical structure and complexity of clauses and sentences remained, however, simple and stereotypical. She still frequently omitted function words and prosody remained affected by scanning of speech. BNT results normalized (51/60).

In the late phase of the stroke (two years postonset neurological symptoms) speech and language had entirely normalized as agrammatism and dysprosodia had resolved.

3.1. Analysis of spontaneous speech and writing

Three video-taped samples of conversational speech obtained 10 days (acute phase), three months (lesion phase) and two years (late phase) poststroke were selected for analysis. Conversational topics were the same for all samples and consisted of the conversational subtest of the AAT (hobbies, profession, family matters). Each sample contained 300 words. Three samples of spontaneous writing, obtained 10 days (acute phase), three months (lesion phase) and two years (late phase) poststroke were also analyzed. Each of these samples consisted of 100 words. The patient wrote about her hobby (buying and selling antiques).

Analysis of phonological, morphosyntactic and lexical characteristics of oral and written language samples was based on the Dutch protocol ‘Analysis of Spontaneous Speech in Aphasia’ (ASTA) (Vereniging voor Klinische linguïstiek, 2003). To obtain a reliable frame of reference, ad-hoc norms for spontaneous speech and written language were collected from five healthy subjects, who were carefully matched for age, gender, handedness and education. As a general cognitive screening test, the controls were examined by the Mini Mental State Examination (MMSE) (Folstein, Folstein, & McHugh, 1975) and the BNT was administered to assess visual confrontation naming and lexical retrieval. Demographic and group characteristics as well as the MMSE and BNT results of the study group and of the patient are presented in table 2.

Table 2: Demographic, MMSE and BNT data of the patient and five matched controls

	EP	C1	C2	C3	C4	C5	Mean	SD
							C1-C5	C1-C5
Age	72;8	70;4	75	72;4	69;10	69;10	71;5	2;2
Education (years)	>10	>10	>10	>10	>10	>10	--	--
Handedness	right	right	right	right	right	right	--	--
MMSE (max. 30)	29	28	27	25	30	29	27.8	1.92
BNT (max. 60)	51	54	50	49	55	53	53	3.39

Legend: C1-C5=control subjects 1 to 5; SD=standard deviation; MMSE=Mini Mental State Examination; max.=maximum score ; BNT=Boston Naming Test

As shown in table 2, mean age of the control group was 71.5 years (SD = 2.2). Like the patient, all members of the control group had more than 10 years of formal education. The control subjects obtained a mean score of 27.8 (SD = 1.92) on the MMSE and a mean score of 53/60 (SD = 3.39) on the BNT. Both scores are well within the normal range (MMSE mean = 27.7; SD = 1.67; BNT mean = 49.2; SD = 3.94).

3.1.1. Spontaneous speech

Phonology and phonetics Analysis of phonological and phonetic characteristics of the spontaneous speech samples at three different time intervals poststroke did not significantly differ from the results obtained in the control population. Although oral language production in the acute and lesion phase was disrupted by scanning of speech (prolonged articulation), speech was generally fluent and well-articulated.

Lexicon Analysis of the lexical characteristics of the patient's spontaneous speech in the acute phase at ten days poststroke (table 3) showed noticeable problems with nouns but not

with verbs. Mann-Whitney U-test revealed the type/token ratio of the nouns to be significantly lower than the control group ($z = -2.9$; $p < .01$). In addition, the patient used fewer empty words - particularly words with a varying reference like *thing* - than the controls ($z = -1.79$; $p < .05$). In the acute phase, she used the same nouns significantly more often than the control group. This type of perseverative verbal behaviour (impaired lexical diversity) only affected nouns, not verbs.

Three months poststroke the patient still experienced more difficulties with nouns than verbs. Two years poststroke, lexical aspects of spontaneous speech had normalized.

Morpho-syntax Ten days postonset neurological symptoms, mean length of utterance (MLU) (= 1.7 words) differed significantly from the MLU of the control subjects (Mean = 8.68; SD = 0.5) ($z = -14.02$; $p < .01$). Quite contradictory, the patient alternated one- and two-word-utterances with the production longer phrases and subordinated clauses (table 3). Three months post-stroke MLU had increased to 6.85 words ($z = -3.68$; $p < .01$). Two years poststroke the patient's MLU was still significantly lower ($z = -3.64$; $p < .01$). The percentage of correct utterances differed significantly from the control group at 10 days ($z = -17.03$; $p = .01$) and three months poststroke ($z = -7.82$; $p < .01$). The finiteness index, a parameter for correctly inflected verbs, also significantly differed at 10 days ($z = -7.91$; $p < .01$) and three months ($z = -3.86$; $p < .01$) postonset. Moreover, the number of prepositions produced in spontaneous speech differed significantly at ten days ($z = -3.58$; $p = .00$) and three months postonset neurological symptoms ($z = -3.18$; $p < .01$). All morphosyntactic parameters, except MLU, had normalized when reinvestigated two years after the stroke.

Table 3: Results of spontaneous speech production (300 words) on ASTA using the ad hoc standard ($n = 5$) at three different time intervals (10 days, 3 months and 2 years poststroke).

	Day 10	z	Month 3	z	Year 2	z	Mean	SD
Phonology and phonetics								
Phonemic paraphasias	0	0	0	0	1	--	0.00	0.00
Phonemic neologisms	0	0.45	0	0.45	0	0.45	0.20	0.45
Seconds incomprehensible	0	0	0	0	0	0	0.00	0.00
Lexicon								
Number nouns	30	-1.4	21*	-2.13	37	-0.19	38.60	8.26
TTR nouns	0.56*	-2.90	0.76	-0.22	0.76	-0.22	0.78	0.07
Number lexical verbs	31	-0.08	46	2.74	32	0.11	31.40	5.32
TTR lexical verbs	0.55	-1.28	0.71	0.75	0.63	-0.28	0.65	0.08
Semantic paraphasias	0	0	0	0	0	0	0	0
Empty words	0	-1.79	0	-1.79	1	-0.67	1.60	0.89
Irrelevant paraphasias	0	-0.45	0	-0.45	0	-0.45	0.20	0.45
Semantic neologisms	0	0	0	0	0	0	0	0
Morpho-syntax								
Modals/Copulas	23	2.69	22	2.38	19	1.47	14.20	3.27
MLU	1.7*	-14.02	6.85*	-3.68	6.86*	-3.64	8.68	0.50
% correct utterances	0.51*	-17.03	0.75*	-7.82	0.97	0.06	0.95	0.03
Finiteness Index	0.7*	-7.91	0.83*	-3.86	0.95	0	0.95	0.03
Number subordinates	5	-0.72	9	0.88	6	-0.32	6.80	2.49
Number prepositions	2*	-3.58	4*	-3.18	20	0.04	19.80	4.97

Legend:* significant $p < 0.05$; TTR=type/token ratio; MLU=mean length of utterance

3.1.2. Analysis of spontaneous writing

Lexicon As reflected by the number of nouns ($z = -0.85$; $p = .20$) and the type/token ratio of nouns ($z = -0.93$; $p = .18$), lexical analysis of the patient's spontaneous writing samples at ten days and two years poststroke did not reveal any significant differences with the control group (table 4). However, at three months poststroke a significant difference was found for

lexical diversity ($z = -2$; $p < .05$). This difference may be explained by the fact that the patient repeatedly wrote about the same topic (going to the market) in the last writing sample.

Morpho-syntax As shown in Table 4, no significant differences were found at the morphosyntactic level between the spontaneous writing samples of the patient and the control group at ten days and three months poststroke. However, analysis of the patient’s spontaneous writing sample produced two years after the stroke disclosed a significant deterioration with regard to the number of correct utterances ($z = -3.31$; $p < .01$) and the finiteness index ($z = -3.75$; $p = .00$). This deterioration may be explained by a lack of practice since the patient mentioned that she had given up writing since the stroke.

Table 4: Results of a written sample analysis of 100 words on ASTA using the ad hoc standard ($n = 5$) at three different time intervals (10 days, 3 months and 2 years poststroke).

	Day 10	z	Month 3	z	Year 2	z	Mean	SD
Lexicon								
Number nouns	19	-0.85	18	-1.18	17	-1.51	21.60	3.05
TTR nouns	0.79	-0.93	0.78	-1.03	0.88	-0.02	0.88	0.10
Number lexical verbs	15	1.40	11	-0.35	13	0.53	11.80	2.28
TTR lexical verbs	0.81	-1.18	0.77*	-2	0.85	-0.56	0.89	0.06
Semantic paraphasias	0		0		0		0	0
Empty words	0		0		0		0	0
Irrelevant paraphasias	0		0		0		0	0
Semantic neologisms	0		0		0		0	0
Morpho-syntax								
Modals/Copulas	5	1.07	3	0.00	1	-1.07	3	1.87
MLU	8.03	-0.14	9.09	0.62	10	1.28	8.23	1.39

% correct utterances	0.92	0.47	1	1.42	0.6*	-3.31	0.88	0.08
Finity Index	0.85	-1.54	1	0.68	0.7*	-3.75	0.95	0.07
Number subordinates	2	0.45	1	-0.30	3	1.19	1.40	1.34
Number prepositions	7	-1.32	11	0.88	10	0.33	9.40	1.82

Legend: * significant $p < 0.05$; TTR=type/token ratio

4. NEUROPSYCHOLOGICAL, BEHAVIOURAL AND AFFECTIVE FINDINGS

Since the patient refused to participate in neuropsychological investigations during the acute and lesion phase of the stroke, psychometric data were only collected in the late phase of the stroke, i.e. two years postonset neurological symptoms. A wide range of neuropsychological tests was performed. To screen for general cognitive impairment, the MMSE was used (Folstein, Folstein, & McHugh, 1975). The Wechsler Adult Intelligence Scale (WAIS-III) (Wechsler, 1997) was administered to measure general intelligence reflected in both verbal and performance abilities. Various aspects of memory function (visual and verbal immediate memory, recent memory, remote memory) were investigated by means of the Wechsler Memory Scale-Revised (WMS-R) (Wechsler, 1987), the memory subtests of the Hierarchic Dementia Scale (HDS) (Cole, & Dastoor, 1987) and the relevant parts of the Repeatable Battery for the Assessment of Neuropsychological Status (RBANS) (Hobart, Goldberg, Bartko, & Gold, 1999). Raven's Coloured Progressive Matrices (CPM) (Raven, 1938) was used to assess visuo-spatial problem solving and inductive reasoning. In addition to immediate and delayed memory, attention, visuo-perceptual abilities and language skills were tested by means of the RBANS. Ideomotor, ideational, drawing and constructional praxis were investigated by means of the praxis subtests of the HDS. The Rey-Osterrieth Figure (Osterrieth, 1944) was used to test visuo-constructional/drawing praxis and visuo-spatial planning and organisation. Frontal executive functions were tested by various tests. The Stroop Colour-Word test (Golden, 1978; Lezak, 1983) was used to investigate the capacity to

inhibit a competing and more automatic response set. The Trail Making Test (Alekoumbides, Charter, Adkins, & Seacat, 1987) was used to examine attention, mental flexibility, visual search and sequencing. The Wisconsin Card Sorting Test (WCST) (Heaton, Chelune, Talley, Kay, & Curtiss, 1993) was administered to measure the ability to form abstract concepts, to shift and maintain goal-oriented cognitive strategies in response to changing environmental contingencies. To assist in identifying frontal, executive dysfunctions the Frontal Assessment Battery was performed (Dubois, Slachevsky, Litvan, & Pillon, 2000). The Meander was used to investigate cognitive flexibility and self-monitoring (Luria, 1966; Lindeboom, & Jonker, 1989). Handedness was formally assessed by means of the Edinburgh Inventory (Oldfield, 1971).

A strong and consistent right hand preference was confirmed by a laterality quotient of +100 on the Edinburgh Handedness Inventory. As shown in table 5, test results on general cognitive measures were normal. The patient obtained a normal score on the MMSE. Full Scale Intelligence Quotient, as measured by the WAIS-III, was within the average range (FSIQ = 90). No significant discrepancy was found between the VIQ (= 95) and PIQ (= 87), which were within the average and low average range, respectively. Standard scores for verbal as well as performance subtest were within normal limits. As demonstrated by normal memory indices on the RBANS, immediate and delayed memory were intact. These findings were confirmed by normal indices on the subparts of the WMS-R. Immediate visual and verbal memory indices as well as the recent memory index were within the average range. Visual cognition was also normal. The patient obtained normal results on visuo-spatial and visuo-constructive tasks (RBANS; Rey-Osterrieth Figure; WAIS-III). A normal result was found for Raven's CPM indicating intact visuo-spatial problem solving and inductive reasoning. As reflected by a concentration index of 79 (M = 100; SD = 15) on the RBANS, sustained visuo-motor concentration and auditory-verbal attention span scored in the lower

range. By contrast, examination of frontal lobe functions revealed selective deficits. Results on the Trial Making Test were within normal limits and as evidenced by a subclinical score on the Stroop Colour-Word test (percentile 12), the ability to inhibit a competing and more automatic response set was depressed. Disruption of frontal planning and conceptual organisation of goal-oriented cognitive strategies was indicated by the results on the Wisconsin Card Sorting Test. The patient did not succeed to complete any category within 128 trials (< pct 1). In comparison to an age and education matched control group, she obtained a standard score of 76 (pc 5) for perseverative responses, which places her in the mildly to moderately impaired range. A strong tendency to perseverate was confirmed by a defective score on the Frontal Assessment Battery at bedside (FAB; Dubois, Slachevsky, Litvan, & Pillon, 2000).

A simplified scoring system qualifying the patient's performance in terms of correct/incorrect was used for the Meander. This test consists of an alternating line pattern printed on a sheet of paper. The patient is asked to continue this line pattern on the sheet using a pencil. The line pattern generated by the patient was classified as incorrect since it was interrupted and disrupted by perseverative errors.

The Middelheim Frontality Score of 8 (cut-off score = 5) (De Deyn, Engelborghs, Saerens, Goeman, Mariën, Maertens, Nagels, Martin, & Pickut, 2005), a clinical and behavioural assessment tool that measures frontal lobe features, was defective. Indeed, during follow-up, affect, mood and behaviour were markedly abnormal. The patient acted in a very childish manner, manifestly exaggerated when expressing her feelings and blunt opinions about personal matters and presented with persisting mood swings and outspoken emotional instability. She often responded to external stimuli in a frontal-like, disinhibited manner, evidenced by inappropriate behaviour, overfamiliarity or flamboyant and impulsive actions.

Table 5: Neurocognitive test results 2 years post stroke

NEUROCOGNITIVE TESTS	Score / Maximum (Standard Score)	Percentile (cut-off)	Mean	±1SD
Mini Mental State Examination	29/30		29	1.67
Intelligence				
Full Scale Intelligence Quotient (FSIQ)	90	25	100	3,0
Verbal IQ (VIQ)	95	37	100	3,0
- Information	(9)	-	(10)	3,0
- Comprehension	(10)	-	(10)	3,0
- Digit Span	(9)	-	(10)	3,0
- Arithmetics	(10)	-	(10)	3,0
- Similarities	(7)	-	(10)	3,0
- Vocabulary	(10)	-	(10)	3,0
- Digit & Letter Repetition	(9)	-	(10)	3,0
Performance IQ (PIQ)	87	19	100	3,0
- Digit Symbol Substitution	(9)	-	(10)	3,0
- Picture Completion	(6)	-	(10)	3,0
- Block Design	(8)	-	(10)	3,0
- Picture Arrangement	(8)	-	(10)	3,0
- Object Assembly	(13)	-	(10)	3,0
- Symbol Search	(7)	-	(10)	3,0
- Matrix Reasoning	(10)	-	(10)	3,0
Raven's Coloured Progressive Matrices	27 / 36	90	50	
RBANS				
- Immediate memory index	(90)	25	100	15
- Visuo-perceptual skills index	(89)	23	100	15
- Language index	(92)	30	100	15
- Attention index	(79)	8	100	15
- Delayed memory index	(101)	53	100	15
Memory				
Wechsler Memory Scale-Revised				
- WMS-R visual memory index	(102)		100	15
- WMS-R verbal memory index	(101)		100	15
- WMS-R recent memory index	(100)		100	15
RBANS				
- Immediate memory index	(90)	25	100	15
- Delayed memory index	(101)	53	100	15
Hierarchic Dementia Scale				
- registration	10/10		9,86	0,35
- remote memory	10/10		10	0
- recent memory	9		9,5	0.88
Praxis				
Rey-Osterrieth Figure				
	36 / 36		35	3
Hierarchic Dementia Scale				
- Ideational : it. 5 HDS	10 / 10		9.79	0.17
- Ideomotor : it. 3 HDS	10 / 10		9.94	0.23
- Drawing : it. 15 HDS	8 / 10		9.81	0.52
- Constructional : it. 12 HDS	8 / 10		10	0
Executive Functions				
Wisconsin Card Sorting				
- number of categories completed	0/128	<1		-

- trials to complete first category	128	≤1		
- failure to maintain set	5	≤1		
- total number of errors	54 (89)	23	38 (100)	(15)
- perseverative responses	65 (76)	5	24 (100)	(15)
- perseverative errors	43 (82)	12	21 (100)	(15)
- nonperseverative errors	11 (109)	73	14-15 (100)	(15)
Stroop Colour-Word Test				
- Card I	56"	25	48"	-
- Card II	65"	52	63"	-
- Card III	130"	12	99"	-
Trail Making Test				
- A	45"	80	80"	-
- B	73"	90	196"	-
Frontal Assessment Battery				
- FAB-score	11/18	(<13)		-

5. DISCUSSION

As the direct result of cerebral vasculopathy caused by Neuro-Sweet disease, this patient incurred several small subcortical white matter lesions and three acute left hemisphere strokes (a larger prefrontal infarction and two small ischemic lesions in the parietal white matter on MRI of the brain). A range of neurobehavioural changes indicated CNS involvement at the onset of the disease. During follow-up the diagnosis of probable Neuro-Sweet syndrome was confirmed by red spot skin lesions and a positive skin biopsy which showed diffuse perivascular inflammatory infiltrates. Three out of the four minor criteria for Neuro-Sweet disease were met as well: fever, inflammatory laboratory values and general malaise (Hisanaga et al., 2005).

Although memory disturbances, dysarthria, jargon aphasia and neuropsychiatric disorders have been recorded in patients with Neuro-Sweet Disease (Hisanaga et al., 2005), cognitive functions have never been thoroughly investigated. In this patient, neurocognitive assessments in the acute phase of the disease revealed striking dissociations. There was no evidence of aphasia, apraxia of speech or dysarthria, but formal language investigations showed a grammatical deficit which selectively affected oral output in the production of spontaneous speech. This is to say that syntax was unimpaired in imposed language tasks such as sentence repetition and the description of situational pictures. Oral reading, dictation

and spontaneous writing were intact as well. In the acute phase of the stroke, spontaneous speech was characterized by severe agrammatism and a telegraphic style. However, formal investigation of syntactic skills at different complexity levels by means of the WEZT (Bastiaanse et al., 2000). did not reveal any evidence of an underlying syntactic impairment. In the lesion phase of the stroke, agrammatism persisted in spontaneous speech production but the telegraphic features receded. In an attempt to further define the characteristics of this syntax disorder, detailed analyses of spontaneous language samples were carried out. Comparison of the patient's results with a carefully matched control group revealed a number of syntactic errors compatible with agrammatism (low scores for finiteness and prepositions, severe problems with free morphemes, function words and verbs, reduced MLU) but also a number of features highly inconsistent with any observations of agrammatism (significantly higher number of modal verbs and copulas, similar number of subordinate clauses as the control group) (Almagro, Sánchez-Casas, & García-Albea, 2005). Although a number of patients with modality specific (Linebarger, Schwartz, & Saffran, 1983; Miceli, Mazzucchi, Menn, & Goodglass, 1983; Caramazza, & Hillis, 1989) and task specific syntactic impairments (Kolk, & Heeschen, 1992; Bastiaanse, 1995) have been described, we are not aware of any patients with agrammatic symptoms confined to spontaneous speech production only. Several of the grammatical phenomena encountered in this patient are quite atypical for a syntax impairment caused by a neurological lesion in the critical language regions of the dominant hemisphere. Firstly, the deviant pattern of selective syntax impairments only affecting spontaneous speech production does not fit in any current model of neurogenic agrammatism (Kolk, & Heeschen, 1992; Grodzinsky, 1986). Secondly, it is generally accepted that the left inferior frontal gyrus of the language dominant hemisphere is crucially implicated in (expressive) syntax processing. Lesion studies have also shown that damage to the adjacent neural structures such as the dominant frontal operculum (Alexander, Naesser, &

Palumbo, 1990), the insula (Dronkers, 1996) and the precentral gyrus (Miceli et al., 1983) may lead to agrammatism and a number of recent case reports have demonstrated that focal damage to the right cerebellum, functionally linked with the prefrontal language areas, may cause expressive and receptive agrammatism as well (Silveri, Leggio, & Molinari, 1994; Mariën, Saerens, Nanhoe, Moens, Nagels, et al., 1996; Fabbro, Skrap, & Aglioti, 2000; Mariën, Engelborghs, Fabbro, & De Deyn, 2001). A detailed literature survey, however, did not reveal one single instance of agrammatism following a causative lesion in the upper BA6 of the language dominant hemisphere. Moreover, the widespread vascular lesions in the subcortical white matter of both hemispheres cannot be held responsible for the agrammatic symptoms either since such lesions have never been found related to syntactic impairment. However, it might be hypothesized that the selective impairment of grammatical speech production is linked to a disruption of the frontosubcortical circuitry involved in expressive language processing. Expressive agrammatism in this patient only occurred in spontaneous speech production; i.e. when lexical-semantic, syntactic, morphological, phonological and articulatory information had to be organised and integrated by the patient herself. The agrammatic features encountered in spontaneous speech might be considered as a higher-level cognitive disorder affecting spontaneous speech organisation at the syntactic level. This selective disorder of grammatical speech organisation might indicate a disruption of the thalamo-frontal circuit subserving the integration of linguistic information, language planning and organisation. In agreement with Fabbro, Peru and Skrap's circuitry model (1997) of language processing, the neurolinguistic data of this patient might suggest a functional disruption of the anterior loop involved in language planning consisting of the prefrontal cortex, the caudate nucleus, the globus pallidus and the ventral anterior nucleus of the thalamus. This view might be supported by both the neurobehavioural and functional neuroimaging findings. Neuropsychological investigations and behavioural observations

revealed a consistent pattern of deficits indicating involvement of the mesial prefrontal and orbitofrontal lobe which provide a pivotal neural substrate for emotion-related processing, inhibitory control of behaviour and goal-directed behaviour (Eslinger, 2008). Disruption of emotional regulation, impaired inhibitory control and self-regulation as well as a change in personality, deficient social judgment and goal-directed behaviour were found. The patient behaved in a childish manner, expressed blunt opinions in a theatrical way, used an unnatural tone (tearful, scanned, and monotone), uttered foul and abusive language and presented with fluctuating mood, abnormal affect and emotional instability. Responses to external stimuli were generally characterized by disinhibited behaviour, manifesting itself as inappropriate behavioural and emotional reactions, overfamiliarity or flamboyant and impulsive actions. Functional disruption of the prefrontal lobes was confirmed by a quantified SPECT study disclosing a significant bilateral decrease of perfusion in the inferior medial prefrontal brain regions.

6. CONCLUSION

This case shows that a constellation of cognitive, affective and behavioural symptoms may be the presenting and most prominent symptoms reflecting CNS involvement of Neuro-Sweet disease. Based on a detailed analysis of the semiological characteristics and lesion-behaviour configurations it seems justified to categorize the selective disturbances of grammatical speech production in this patient as a disruption of the frontosubcortical circuitry involved in language production. A range of prefrontal neurobehavioural abnormalities associated with functional disruption of the inferior medial frontal regions as demonstrated by SPECT, suggest that the agrammatic symptoms in this patient may be linked to a higher-level cognitive disorder following encephalopathic central nervous system involvement. Since the choice of treatment and therapeutic outcome depend on a correct identification of the nature

of the disorder, it is of crucial importance to critically explore atypical cognitive and behavioural phenomena in patients with vascular brain lesions.

7. REFERENCES

Alekoubides, A., Charter, R.A., Adkins, T.G., & Seacat, G.F. (1987). The diagnosis of brain damage by the WAIS, WMS and Reitan Battery utilizing standardized scores corrected for age and education. *International Journal of Clinical Neuropsychology*, 9, 11-28.

Alexander, M.P., Naesser, M.A., & Palumbo, C. (1990). Broca's area aphasias: aphasia after lesions including the frontal operculum. *Neurology*, 40, 353-362.

Almagro, Y., Sánchez-Casas R.M., & García-Albea, J.E. (2005). El agramatismo y su sintomatología. *Revista Neurológica Clínica*, 40, 369-380.

Bastiaanse, R. (1995). Broca's aphasia: a syntactic and/or morphological disorder? A case study. *Brain and Language*, 48, 1-32.

Bastiaanse, R., Maas, E., & Rispens, J. (2000). *Werkwoorden en Zinnentest*. Swets & Zeitlinger. Lisse.

Caramazza, A., & Hillis, A.E. (1989). The disruption of Sentence Production: Some dissociations. *Brain and Language*, 36, 625-650.

Cohen, P.R. (2007) Sweet's syndrome- a comprehensive review of an acute febrile neutrophilic dermatosis. *Orphanet Journal of Rare Diseases*, 2, 34.

Cole, M., & Dastoor, D. (1987). A new hierarchic approach to the measurement of dementia. *Psychosomatics*, 28, 298-305.

De Deyn, P.P, Engelborghs, S., Saerens, J., Goeman, J., Mariën, P., Maertens, K., Nagels, G., Martin, J.J., & Pickut, B.A. (2005). The Middelheim Frontality Score: a behavioural assessment scale that discriminates frontotemporal dementia from Alzheimer's disease. *International Journal of Geriatric Psychiatry*, 20, 70-79.

De Renzi, E., & Vignolo, L.A. (1962). The token test: A sensitive test to detect receptive disturbances in aphasics. *Brain*, 85, 665-678.

Doesborgh, S.J.C., Van de Sandt-Koenderman, W.M.E., Dippel, D.W.J., Van Harskamp, V.F., Koudstaal, P.J., & Visch-Brink, E.G. (2003). Linguistic deficits in the acute phase of stroke. *Journal of Neurolinguistics*, 250, 977- 982.

Dronkers, N.F. (1996). A new brain region for coordinating speech articulation. *Nature*, 384, 159-161.

Dubois, B., Slachevsky, A., Litvan, I., & Pillon, B. (2000). The FAB: a Frontal Assessment Battery at bedside. *Neurology* 55, 1621-1626.

Eslinger, P. (2008). The frontal lobe: executive, emotional, and neurological functions. In: Mariën, P. & Abutalebi, J. (Eds.), *Neuropsychological Research: a review*, Psychology Press, Hove, 397-408.

Fabbro, F., Skrap, M., & Aglioti, S. (2000). Pathological switching between languages after frontal lesions in a bilingual patient. *Journal of Neurology, Neurosurgery and Psychiatry*, *68*, 650-652.

Folstein, M., Folstein, S., & McHugh, P. (1975). Mini-Mental State: a practical method for grading the cognitive state of patients for the clinician. *Journal of Psychiatric Research*, *12*, 189-198.

Fukae, J., Noda, K., Fujishima, K., Wada, R., Yoshiike, T., Hattori, N., et al. (2007). Successful treatment of relapsing neuro-Sweet's disease with corticosteroid and dapsone combination therapy. *Clinical Neurology and Neurosurgery*, *109*, 910-913.

Fukushima, K., Hineno, A., Kodaira, M., Machida, K., Ishii, W., Kaneko, T., et al. (2008). Reversible extensive leukoencephalopathy in Sweet disease: a case report. *Journal of the Neurological Sciences*, *275*, 178-180.

Golden, C.J. (1978) *Stroop Color and Word Test: a manual for clinical and experimental uses*. Stoelting, Chicago (IL).

Goodglass, H., & Kaplan, E. (1983). *The Assessment of Aphasia and Related Disorders*. Lea & Febiger, Philadelphia.

Graetz, P., De Bleser R., & Willmes, K. (1986). *De Akense AfasieTest*. Swets & Zeitlinger, Lisse.

Grodzinsky, Y. (1986). Language deficits and the theory of syntax. *Brain and Language*, 27, 135-159.

Heaton, R.K., Chelune, G.J., Talley, J.L., Kay G.G., & Curtiss, G. (1993). *Wisconsin Card Sorting Test Manual: revised and expanded (WCST)*. Odessa, Psychological Assessment Resources.

Hiari, N. & Borland, C. (2009). A 47-year-old man with Neuro-Sweet syndrome in association with Crohn's disease: a case report. *Journal of Medical Case Reports*, 3, 8997.

Hisanaga, K., Iwasaki, Y., & Itoyama, Y. (2005). Neuro-Sweet disease. Clinical manifestations and criteria for diagnosis. *Neurology*, 64, 1756-1761.

Hisanaga, K., Hosokawa, M., Sato, N., Mochizuki, H., Itoyama, Y., & Iwasaki, Y. (1999). "Neuro-sweet disease": benign recurrent encephalitis with neutrophilic dermatosis. *Archives of Neurology*, 56, 1010-1013.

Hobart, M.P., Goldberg, R. Bartko J.J., & Gold, J.M. (1999). Repeatable Battery for the Assessment of Neuropsychological Status as a screening test in schizophrenia, II: Convergent/discriminant validity and diagnostic group comparisons. *American Journal of Psychiatry*, 156, 1951–1957.

Jiro, F., Kazuyuki, N., Kenji, F., Ryo, W., Takashi, Y., Nobutaka H. et al. (2007). Successful treatment of relapsing neuro-Sweet's disease with corticosteroid and dapsone combination therapy. *Clinical Neurology and Neurosurgery*, 109, 910–913.

Kaplan, E., Goodglass H., & Weintraub, S. (1983). *The Boston Naming Test*. Lea and Febiger, Philadelphia.

Kolk H.H.J., & Heeschen, C. (1992). Agrammatism, paragrammatism and the management of language. *Language and Cognitive Processes*, 7, 89-129.

Lezak, M.D. (1983). *Neuropsychological Assessment*. Oxford University Press, New York.

Lindeboom, J., & Jonker, C. (1989). *Amsterdamse Dementie-Screeningstest ADS6. Handleiding*. Swets & Zeitlinger, Lisse.

Linebarger, M.C., Schwartz M.F., & Saffran, E.M. (1983). Syntactic processing in agrammatism: a reply to Zurif and Grodzinsky. *Cognition*, 15, 207-214.

Luria, A. R. (1966). *Human Brain and Psychological Processes*. Harper & Row, New York.

Mariën, P, Saerens, J., Nanhoe, R., Moens, E., Nagels, G., Pickut, B.A., et al. (1996). Cerebellar induced aphasia: case report of cerebellar induced prefrontal aphasic language phenomena supported by SPECT findings. *Journal of the Neurological Sciences*, 144, 34-43.

Mariën, P., Mampaey, E., Vervaet, A., Saerens, J., & De Deyn, P.P. (1998). Normative data for the Boston Naming Test in native Dutch speaking elderly. *Brain and Language*, 65, 447-467.

Mariën, P., Engelborghs, V., Fabbro, F., & De Deyn, P.P. (2001). The Lateralized Linguistic Cerebellum: A Review and a New Hypothesis. *Brain and Language*, 79, 580-600.

Miceli, G., Mazzucchi, A., Menn, L., & Goodglass, H. (1983). Contrasting cases of Italian agrammatic aphasia without comprehension disorder. *Brain and Language*, 19, 65-97.

Oldfield, R. (1971). The assessment and analysis of handedness: the Edinburgh inventory. *Neuropsychologia*, 9, 97-113.

Osterrieth, P.A. (1944). Le test de copie d'une figure complexe. *Archives of Psychology*, 30, 205-353.

Raven, J.C. (1938). *Progressive Matrices: a perceptual test of intelligence*. H.K. Lewis, London.

Silveri, M.C., Leggio, M.G., & Molinari, M. (1994). The cerebellum contributes to linguistic production: a case of agrammatic speech following a right cerebellar lesion. *Neurology*, 44, 2047-2050.

Siva, A., & Saip, S. (2009). The spectrum of nervous system involvement in Behçet's syndrome and its differential diagnosis. *Journal of Neurology*, 256, 513-529.

Sweet, R.D. (1964). An acute febrile neutrophilic dermatosis. *British Journal of Dermatology*, 76, 349-356.

Vereniging voor Klinische linguïstiek. (2003). *Analyse voor Spontane Taal bij Afasie*.

Wechsler, D. (1987). *Manual for the Wechsler Memory Scale-Revised*. Psychological Corporation, New York.

Wechsler, D. (1997). *WAIS-III, Nederlandstalige bewerking, technische handleiding*. Swets Test Publishers, Lisse.

Legend to Figures

Figure 1 (A-J): Brain MRI axial FLAIR slices (A-E) 10 days poststroke disclosed widespread small subcortical white matter and basal ganglia lesions and a larger infarction in BA6 (at a depth of 1.5 cm) of the left hemisphere. Diffusion-weighted imaging (DWI) of the brain (F-J) showed in addition to the acute prefrontal infarction, two additional small acute ischemic lesions in the white matter of the left parietal lobe.

Figure 2: Quantified Tc-99m-ECD SPECT perfusion scan of the brain at seven days poststroke demonstrating a significant decrease of perfusion in the left ($z = -2.18$; $p = .02$) and the right ($z = -3.83$; $p = .00$) inferior medial frontal regions.