



## City Research Online

### City, University of London Institutional Repository

---

**Citation:** Crerar-Gilbert, A. J., Kyriacou, P. A., Jones, D. P. & Langford, R. M. (2002). Assessment of photoplethysmographic signals for the determination of splanchnic oxygen saturation in humans. *Anaesthesia*, 57(5), pp. 442-445. doi: 10.1046/j.0003-2409.2001.02453.x

This is the accepted version of the paper.

This version of the publication may differ from the final published version.

---

**Permanent repository link:** <https://openaccess.city.ac.uk/id/eprint/14677/>

**Link to published version:** <https://doi.org/10.1046/j.0003-2409.2001.02453.x>

**Copyright:** City Research Online aims to make research outputs of City, University of London available to a wider audience. Copyright and Moral Rights remain with the author(s) and/or copyright holders. URLs from City Research Online may be freely distributed and linked to.

**Reuse:** Copies of full items can be used for personal research or study, educational, or not-for-profit purposes without prior permission or charge. Provided that the authors, title and full bibliographic details are credited, a hyperlink and/or URL is given for the original metadata page and the content is not changed in any way.

---

City Research Online:

<http://openaccess.city.ac.uk/>

[publications@city.ac.uk](mailto:publications@city.ac.uk)

---

# Assessment of photoplethysmographic signals for the determination of splanchnic oxygen saturation in humans

A. J. Crerar-Gilbert,<sup>1</sup> P. A. Kyriacou,<sup>2</sup> D. P. Jones<sup>3</sup> and R. M. Langford<sup>4</sup>

*1 Clinical Research Fellow and 4 Director, Anaesthetics Laboratory, St Bartholomew's Hospital, Barts and the London NHS Trust, London EC1A 7BE, UK*

*2 Lecturer and 3 Reader, Medical Electronics & Physics, Department of Engineering, Queen Mary, University of London, London E1 4NS, UK*

## Summary

The need for a clinically applicable method of detecting splanchnic hypoxia has led to experimental animal studies which indicated the usefulness of intestinal pulse oximetry. Pulse oximetry relies on detection of photoplethysmographic signals. Before developing a pulse oximeter for the measurement of organ oxygen saturation peri-operatively, we designed a system based on a reflectance photoplethysmographic probe to investigate photoplethysmographic signals from human viscera (bowel, liver, and kidney). Recordings were obtained simultaneously from the abdominal viscera and the finger using identical probes. The probe was held sequentially for up to 2 min on the surface of viscera of 12 patients during routine laparotomy. Measurable splanchnic photoplethysmographic signals were recorded for the first time in humans. There were no statistically significant differences between photoplethysmographic amplitudes from viscera and those from the finger. Our results indicate the feasibility of pulse oximetry for the measurement of visceral oxygenation in humans.

**Keywords** *Viscera: blood supply. Photoplethysmography: reflectance. Oximetry.*

.....

At present there is no simple, rapid and widely applicable method for measuring directly internal tissue and organ oxygenation peri-operatively. However, the concept has been used in animal studies [1–4], in which pulse oximetry was found useful in estimating tissue blood flow [1] and bowel ischaemia [2–4]. Pulse oximeters estimate arterial oxygen saturation ( $S_{pO_2}$ ) by shining light at two different wavelengths, red and infrared, through vascular tissue. In this method the pulsatile photoplethysmographic (PPG) signal associated with cardiac contraction is assumed to be attributable solely to the arterial blood component. The amplitudes of the red and infrared pulsatile photoplethysmographic signals are sensitive to changes in  $S_{pO_2}$  because of differences in the light absorption of oxygenated and deoxygenated haemoglobin. From the ratios of these amplitudes and the corresponding non-pulsatile photoplethysmographic components,  $S_{pO_2}$  is calculated. Hence, the presence of a measurable pulsatile photoplethysmographic signal is essential for

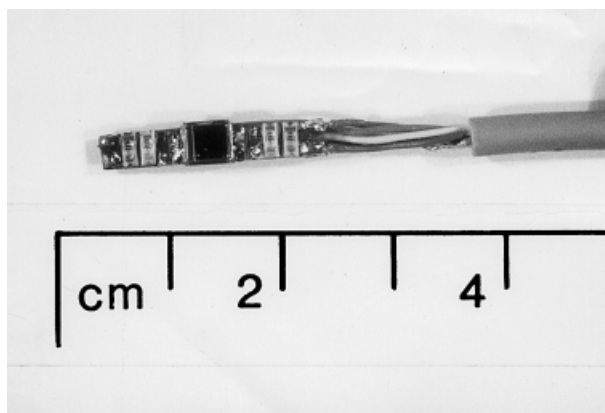
the successful operation of a pulse oximeter. The aim of this pilot study was to investigate the quality and morphology of human abdominal organ photoplethysmographic signals during laparotomy recorded with a purpose-built reflectance photoplethysmographic probe, and to compare their amplitudes with those obtained concurrently from an identical probe on a finger.

## Methods

After obtaining approval from the Local Research Ethics Committee and informed, written consent, 12 adult patients undergoing elective laparotomy under general anaesthesia were studied. The study was observational and patients' surgical and anaesthetic management were as per routine. Induction of anaesthesia with 2–3 mg.kg<sup>-1</sup> propofol and 1–2 µg.kg<sup>-1</sup> fentanyl was followed by 0.5 mg.kg<sup>-1</sup> atracurium, tracheal intubation and

intermittent positive pressure ventilation. Anaesthesia was maintained with 1–2% isoflurane and 50–70% nitrous oxide in oxygen. Patients received boluses of fentanyl, morphine and atracurium as clinically indicated. All patients were haemodynamically stable and well oxygenated.

A reflectance photoplethysmographic probe consisting of miniaturised light emitters, with peak emission wavelengths at 880 nm (infrared) and 655 nm (red) and a photodetector, has been developed (Fig. 1) [5, 6]. Two identical reflectance photoplethysmographic probes were used simultaneously for recording signals from the abdominal viscera and from the finger. Both probes were connected to an electrically isolated data acquisition and processing system, with fixed identical gain for each channel, and red and infrared PPG signals were displayed on a laptop computer [5, 6]. A commercially available transmission type pulse oximeter probe was also placed on an adjacent finger. The photoplethysmographic probe for visceral measurements was inserted into a sealed, disposable 20-FG gastric tube. Sealing of the sterile gastric tube, for prevention of contamination, was achieved aseptically by cutting off the blind tip and inserting it retrogradely into the distal lumen. The photoplethysmographic probe, mounted on the end of a semirigid cable, was then passed down the gastric tube to its final position with the probe approximately 0.5 cm from the sealed end. The gastric tube containing the probe was then gently applied to the surface of each abdominal organ so that the emitted light was reflected from their surfaces. General theatre and operating lights were switched off. The probe was kept in place until a stable photoplethysmographic signal was achieved, for up to 2 min per organ. Statistical analysis with paired Student's *t*-test was used to compare the amplitude of



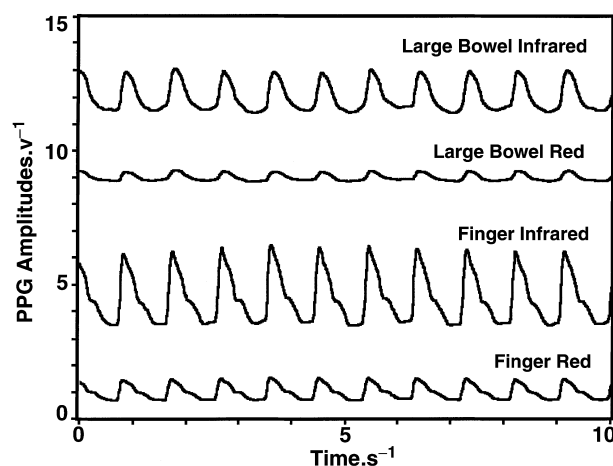
**Figure 1** Reflectance visceral photoplethysmographic probe used to measure splanchnic oxygen saturation.

each abdominal organ signal with that recorded simultaneously from the finger. Statistical significance was assumed at  $p < 0.05$ .

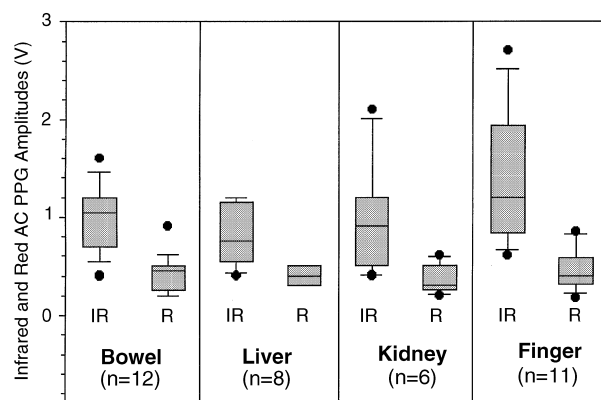
## Results

Seven women and five men were studied, ranging in age between 29 and 78 years. The signals were recorded from the surface of the bowel in all 12 patients and in some patients, depending on intra-operative accessibility, also from the liver and the kidney.

Measurable signals were always obtained from the abdominal organs. Typical photoplethysmographic traces obtained from the bowel and the finger at both wavelengths are shown in Fig. 2 and recordings from all sites



**Figure 2** Typical pulsatile photoplethysmographic traces from simultaneous measurements on the bowel and finger.



**Figure 3** Box and whiskers plots for the abdominal and finger pulsatile photoplethysmographic signals at infrared (IR) and red (R) wavelengths, showing the median (horizontal line), 25th and 75th percentiles (box), 10th and 90th percentiles (whiskers) and range (solid points). In some cases these values overlap and do not appear on the plots.

are shown in Fig. 3. Signal amplitudes from the abdominal organs were not statistically different from those recorded from the finger for the red and infrared wavelengths.

## Discussion

Splanchnic organs are particularly vulnerable to hypoperfusion. Intestinal ischaemia may occur intra-operatively or in critically ill patients with low flow states of cardiogenic or hypovolaemic origin, severe inflammation such as systemic inflammatory response syndrome or severe infection. Splanchnic ischaemia may ultimately lead to cellular hypoxia and necrosis, and may well contribute to the development of multiple organ failure and increased mortality [7]. Rapid detection of a significant change in tissue oxygenation could enable earlier and more successful intervention and aggressive restoration of splanchnic blood flow, which has been shown to improve survival in critically ill patients [7].

Techniques used to measure tissue oxygenation such as polarographic oxygen electrodes, luminescent oxygen probes, magnetic resonance spectroscopy and positron emission tomography remain research tools [7]. Manual fluid gastric tonometry, the most commonly used technique for estimating intestinal hypoxia, is relatively expensive, intermittent, operator-dependent and time consuming [8]. There is thus a need for a simple, reliable, non-invasive and continuous method for estimating organ blood oxygen saturation, which would be useful intra-operatively and in critical care. Methods such as surface pulse oximetry, Doppler ultrasound and intravenous fluorescein have been investigated to assess intestinal ischaemia in dogs, pigs and rabbits [1–4]. Doppler ultrasound and intravenous fluorescein were found to be subjective and non-quantitative. Moreover they are indicative of blood flow and not tissue oxygenation. The studies showed that surface pulse oximetry was rapid and reproducible, as well as highly sensitive and specific for detecting small bowel ischaemia [2–4]. Intestinal  $S_pO_2$  measured with pulse oximetry correlated well with intestinal surface tissue oxygen tension measured with a Clark electrode, and tissue blood flow as detected with radiolabelled microspheres [1]. Accuracy of pulse oximetry in the diagnosis of bowel ischaemia was confirmed by histological analysis [3, 4]. Ouriel *et al.* [9] used pulse oximetry in humans for detecting colonic ischaemia after abdominal aneurysm surgery. They showed that pulse oximetry was indicative of bowel ischaemia in that clinical setting but their study had two main limitations. First, the authors used a commercially available ‘clip on’ finger probe. A commercial finger probe is not only difficult to sterilise but it may also compress bowel tissue

resulting in reduced blood flow and oxygenation. A second limitation was that the signals were described only qualitatively.

To avoid the limitations of a commercial pulse oximeter in our study we used a purpose built miniature reflectance photoplethysmographic probe. This probe was designed to fit into a disposable, sterile nasogastric tube and to avoid pressure on the viscera. Ultimately, the probe may be left *in situ* on the abdominal viscera postoperatively for continuous monitoring of tissue perfusion in patients at high risk of developing visceral ischaemia. As the emission characteristics of our reflection probe are similar to those of a commercial finger transmission pulse oximeter, it is reasonable to suggest that the reflected light reaching the detector has originated from all bowel layers. However, further investigations during conditions of impaired bowel perfusion are required to show that this technique may reliably discriminate between normal and abnormal states.

In contrast to Ouriel *et al.*'s study [9], the objective of this preliminary study was to quantify photoplethysmographic signals obtained by a practical reflectance surface probe, to determine whether there would be sufficient photoplethysmographic amplitudes at red and infrared wavelengths from various abdominal organs to make pulse oximetry feasible. Measurable photoplethysmographic signals were detected for the first time from both hollow and solid human abdominal viscera comparable with the finger photoplethysmographic amplitudes. This is in agreement with animal studies, which show a good correlation between signals from normally perfused small intestine and tissues such as tongue [3] and skin [2]. These findings do not appear to have been reported previously and indicate the feasibility of reflectance pulse oximetry for measuring the oxygenation of abdominal organs, and the rationale for following with longer term studies.

## Acknowledgements

We would like to thank the Joint Research Board of St Bartholomew's Hospital for funding, and Professor N. Williams and surgical colleagues for their kind support.

## References

- 1 MacDonald PH, Dinda PK, Beck IT, Mercer CD. The use of oximetry in determining intestinal blood flow. *Surgery, Gynecology and Obstetrics* 1993; **176**: 451–8.
- 2 Ferrara JJ, Dyess DL, Lasecki M, Kinsey S, Donnell C, Jurkovich G. Surface oximetry. A new method to evaluate intestinal perfusion. *The American Surgeon* 1988; **54**: 10–4.

- 3 DeNobile J, Guzzetta P, Patterson K. Pulse oximetry as a means of assessing bowel viability. *Journal of Surgical Research* 1990; **48**: 21–3.
- 4 Pearce W, Jones D, Warren G, Bartle E, Whitehill T, Rutherford R. The use of infrared photoplethysmography in identifying early intestinal ischemia. *Archives of Surgery* 1987; **122**: 308–10.
- 5 Kyriacou PA, Moye AR, Choi DMA, Langford RM, Jones DP. A system for investigating oesophageal photoplethysmographic signals in anaesthetised patients. *Medical and Biological Engineering and Computing* 1999; **37**: 639–43.
- 6 Kyriacou PA, Moye AR, Choi DMA, Langford RM, Jones DP. Investigation of the human oesophagus as a new monitoring site for blood oxygen saturation. *Physiological Measurement* 2001; **22**: 223–32.
- 7 Jury of the Consensus. 3rd European Consensus Conference in Intensive Care Medicine. Consensus Report. Tissue hypoxia. How to detect, how to correct, how to prevent? *Intensive Care Medicine* 1996; **22**: 1250–7.
- 8 Kolkman J, Otte J, Groeneveld A. Gastrointestinal luminal  $PCO_2$  tonometry. an update on physiology, methodology and clinical applications. *British Journal of Anaesthesia* 2000; **84**: 74–86.
- 9 Ouriel K, Fiore WM, Geary JE. Detection of occult colonic ischaemia during aortic procedures: Use of an intraoperative photoplethysmographic technique. *Journal of Vascular Surgery* 1988; **7**: 5–9.