



## City Research Online

### City, University of London Institutional Repository

---

**Citation:** Campbell, P., Redmond, T., Agarwal, R.K., Marshall, L. K. & Evans, B. J. W. (2015). Repeatability and comparison of clinical techniques for anterior chamber angle assessment. *Ophthalmic and Physiological Optics*, 35(2), pp. 170-178. doi: 10.1111/opo.12200

This is the accepted version of the paper.

This version of the publication may differ from the final published version.

---

**Permanent repository link:** <https://openaccess.city.ac.uk/id/eprint/13638/>

**Link to published version:** <https://doi.org/10.1111/opo.12200>

**Copyright:** City Research Online aims to make research outputs of City, University of London available to a wider audience. Copyright and Moral Rights remain with the author(s) and/or copyright holders. URLs from City Research Online may be freely distributed and linked to.

**Reuse:** Copies of full items can be used for personal research or study, educational, or not-for-profit purposes without prior permission or charge. Provided that the authors, title and full bibliographic details are credited, a hyperlink and/or URL is given for the original metadata page and the content is not changed in any way.

---

City Research Online:

<http://openaccess.city.ac.uk/>

[publications@city.ac.uk](mailto:publications@city.ac.uk)

---

**Full Title: Repeatability and Comparison of Clinical Techniques for Anterior Chamber Angle Assessment**

**Abbreviated Title: Repeatability and Comparison of ACA Assessment Techniques**

**Authors:**

Peter Campbell<sup>1,2,3</sup>

Tony Redmond<sup>4,2</sup>

Rishi Agarwal<sup>2,3</sup>

Lewis R Marshall<sup>5</sup>

Bruce JW Evans<sup>2,3,5</sup>

1. Ophthalmology, St Thomas' Hospital, Westminster Bridge Road, London, SE1 7EH
2. Institute of Optometry, Neville Chappell Research Clinic, 56-62 Newington Causeway, London, SE1 6DS
3. London South Bank University, Faculty of Health and Social Care, 103 Borough Road, London, SE1 0AA
4. School of Optometry and Vision Sciences, Cardiff University, Maindy Road, Cardiff, CF24 4HQ
5. Cole Martin Tregaskis Optometrists, 23 Shenfield Road, Brentwood, Essex, CM15 8AG

Corresponding author: Peter Campbell, Ophthalmology, St Thomas' Hospital, Westminster Bridge Road, London SE1 7EH. Email address: [peter.campbell@gstt.nhs.uk](mailto:peter.campbell@gstt.nhs.uk)

Keywords: Gonioscopy, anterior chamber, anterior segment, AS-OCT, Van Herick, imaging

**Disclosure:** Topcon Limited (Topcon Europe, Medical B.V, Netherlands) for the loan of a Topcon-OCT machine

### **Acknowledgements**

This work was supported by a College of Optometrists iPro Small Grants Scheme Award. We thank Professor Nicola Crichton of London South Bank University for help with statistical analysis.

### **Title of Study:**

### **Repeatability and Comparison of Anterior Chamber Angle Assessment Tests**

## **Abstract**

### **Purpose**

To assess the repeatability of gonioscopy, van Herick method and anterior segment Optical Coherence Tomography (AS-OCT) and determine the agreement between these techniques within a community optometry setting.

### **Methods**

Gonioscopy, van Herick method and AS-OCT imaging were performed by an optometrist on two occasions, one month apart, on 80 subjects aged over 40 years recruited from community optometry practices. Anterior segment images were captured with a spectral domain OCT (Topcon 3D OCT-2000; wavelength 840nm) set to the Anterior Segment (AS) mode. Eyes were graded as open or occludable for each method. AS-OCT images from both visits were graded by a second optometrist masked to the gonioscopy and van Herick method results, and the visit on which the images were acquired. Cohen's kappa ( $\kappa$ ) was used to describe the intra-observer repeatability. Likelihood ratios, sensitivity and specificity of van Herick method and AS-OCT were calculated, using gonioscopy as the reference standard.

### **Results**

Measurements were obtained from 80 eyes of 80 subjects. In four cases, AS-OCT images were un-gradable due to difficulty in locating the scleral spur. The repeatability of gonioscopy was

fair  $\kappa=0.29$ , while that of the van Herick method ( $\kappa=0.54$ ) and AS-OCT ( $\kappa=0.47$ ) were somewhat better. The van Herick method showed good sensitivity (visit 1: 75%, visit 2: 69%) and high specificity (visit 1: 88%, visit 2: 96%). The sensitivity of AS-OCT was fair (visit 1: 46%, visit 2: 25%), but specificity was high (visit 1: 87%, visit 2: 89%).

### **Conclusion**

Intra-observer repeatability was better for van Herick method and for AS-OCT than for gonioscopy, despite the latter being considered the gold standard method. The van Herick method appeared to be more sensitive than AS-OCT when identifying eyes at risk of angle closure. A standalone anterior segment OCT with a longer wavelength laser could afford better visualisation of the angle, and might therefore be expected to enable the examiner to make more precise classifications. These instruments are not widely used by optometrists in clinical practice in the UK at present.

## Introduction

Primary angle closure glaucoma (PACG) is a major cause of blindness worldwide and is responsible for nearly half of all blindness caused by glaucoma.<sup>1</sup> The prevalence of PACG is greatest in Asian populations, ranging from 0.80% in India to 1.26% in China.<sup>1</sup> The prevalence in a European population is estimated at 0.4% in people over 40 years. In the UK, due to the ageing population and increasing life longevity, the number of cases of PACG is expected to increase by 19% over the next decade.<sup>2</sup>

Assessment of the anterior chamber angle (ACA) is essential for the detection of eyes at risk of PACG prior to the onset of the disease.<sup>3</sup> Gonioscopy is currently considered the gold standard method to assess the ACA.<sup>4</sup> In the UK, the National Institute for Health and Clinical Excellence (NICE) guidance on the diagnosis and management of chronic open angle glaucoma (COAG) and ocular hypertension (OHT) recommends the use of gonioscopy to confirm diagnosis of COAG or OHT.<sup>5</sup> National guidance from Australia and USA on glaucoma diagnosis also recommends the use of gonioscopy to assess the ACA.<sup>6,7</sup>

Gonioscopy is a clinically demanding test. It is not always well tolerated by patients, and may be time-consuming in a busy clinic.<sup>8</sup> It relies on subjective assessment of the ACA in real time<sup>4</sup> and requires considerable clinical skill and experience.<sup>9</sup> Despite being the gold standard method of assessing the ACA, gonioscopy is currently not a General Optical Council-mandated core competency for UK optometrists and is not routinely carried out by optometrists in UK community practice.<sup>10</sup> A recent survey showed that only 15% of UK community optometrists had access to a gonioscopy lens.<sup>11</sup> In Australia and New Zealand, optometrists with therapeutic licences have been shown to have greater confidence in performing gonioscopy than those without such a licence.<sup>12</sup>

The van Herick method of estimating the limbal chamber depth is widely used by optometrists as a screening test to identify an occludable ACA. The College of Optometrists recommends performing this test when examining patients at risk from glaucoma.<sup>13</sup> It has been shown to have good sensitivity and specificity at predicting occludable ACAs, with gonioscopy as the reference standard.<sup>8</sup>

Anterior Segment Optical Coherence Tomography (AS-OCT) is a relatively new method for assessing the ACA. This technique uses the principle of low-coherence interferometry to produce cross sectional images of the anterior segment.<sup>14</sup> AS-OCT is relatively quick and easy to carry out, and is considered a semi-objective method of assessing the ACA.<sup>15,16</sup> It has been shown to have good sensitivity in Asian populations (again, with gonioscopy as the reference standard).<sup>15</sup> There is a lack of evidence, however, on the relative performance of gonioscopy and other methods of ACA assessment in non-Asian populations, where the prevalence of PACG, although less than in Asia, is still considerable and rising.

## **Purpose**

The aims of this study are to investigate the repeatability of gonioscopy, van Herick method and AS-OCT in ACA assessment and the ability of the van Herick method and AS-OCT at detecting eyes at risk of PACG within a community optometry setting. Repeatability is defined, in this study, as a measure of device variability when used by a single observer,<sup>17</sup> in a timeframe within which change in the anterior chamber angle status is unlikely to have taken place.

## **Methods**

Eighty-five subjects were invited to participate in this study. The Bland and Altman formula for inter-method agreement was used to calculate the sample size.<sup>18</sup> The number of repeated measures in our study is 2 and a confidence interval of 15% was chosen to give an acceptable level of precision.

Ethical approval was obtained by the Camberwell and St Giles NHS National Research Ethics Committee. Subjects aged  $\geq 40$  years were recruited from two optometry practices; one in central London and one in Essex. Inclusion criteria were an optometric eye examination within the previous year, including those diagnosed with glaucoma (both open angle and angle closure) or established by their optometrist to be at risk of glaucoma (e.g. ocular

hypertension, narrow anterior chamber angles, or with a family history of glaucoma). Exclusion criteria were corneal disorders, recent eye infection, ocular inflammation (within the previous 6 months), previous refractive surgery, peripheral iridotomy or intra-ocular surgery.

Participants were invited to attend for a series of tests (van Herick limbal chamber depth assessment, gonioscopy and AS-OCT imaging) on two occasions approximately one month apart. This was considered an acceptable time period within which any chronic change in the ACA would be unlikely. All tests were undertaken by one optometrist (PC, one of the authors) who had previously received training in gonioscopy by a glaucoma consultant ophthalmologist and has worked for the past five years in a hospital based glaucoma shared care scheme.

#### **Van Herick - Limbal Chamber Depth Assessment**

The van Herick method is based on a comparison of the depth of the peripheral anterior chamber to the thickness of the cornea. A narrow vertical beam is directed at the temporal limbus, offset by 60°. The beam is positioned at the most peripheral point of the cornea (next to the limbus), where a clear view of the anterior iris interface, posterior cornea and anterior cornea are just visible simultaneously. The ACA is assessed by estimating the ratio of the peripheral anterior chamber depth to the thickness of the corneal section.<sup>19</sup> Measurements were taken at the temporal and nasal limbus. The angle is traditionally graded as one of four categories (van Herick angles 1-4), however Foster et al<sup>8</sup> introduced a seven grade percentage system to improve precision of the test. In this system, anterior chamber depth is estimated as a percentage of the thickness of the cornea

Table 1 shows a comparison between the two grading schemes. The modified grading system of Foster et al was used in the current study.



Table 1 The original van Herick grading system and corresponding grades in the modified system of Foster et al.<sup>8</sup>

Van Herick Original Grading System	Ratio of AC depth compared to corneal thickness	Modified Grading System (Foster et al, 2000)
Grade 4	≥1:1	≥100% 75%
Grade 3	0.25 to 0.50:1	40%
Grade 2	0.25:1	25%
Grade 1	< 0.25:1	15% 5% 0%

Van Herick was carried out in low illumination (<5 lux) and care was taken to prevent light from the slit lamp falling on the pupil during the test. For the purpose of this study, an eye was defined as “occludable” (at risk of angle closure) with the van Herick method if the grading was <25% for either the nasal or temporal angle.

### Gonioscopy

The test was performed with a one mirror hand held MagnaView gonioscopy lens (Ocular Instruments Inc., Bellevue, WA, <http://www.ocularinc.com>). Oxybuprocaine Hydrochloride 0.4% eye drops (Chauvin Pharmaceuticals Ltd, Surrey, UK) were instilled to anaesthetise the cornea and a coupling agent (Viscotears Gel, polyacrylic acid 0.2%, Novartis AG Switzerland) was applied to the lens. The assessment was carried out with high magnification (x16), a 1mm beam was reduced to a narrow slit, a vertical beam was offset horizontally to assess the superior and inferior angles and offset vertically for the nasal and temporal angles. The patient was instructed to adopt the primary position and slight tilting of the lens was permitted, to gain an adequate view where necessary.<sup>4</sup>

Gonioscopy was carried out in low illumination (<5 lux) and care was taken to prevent light from the slit lamp falling on the pupil during the test. The angle was graded for each quadrant using the modified Shaffer convention, by which each grade corresponds to the visibility of the different angle structures.<sup>20</sup> Figure 1 shows the structures of a normal ACA and Table 2 outlines the grading scheme.

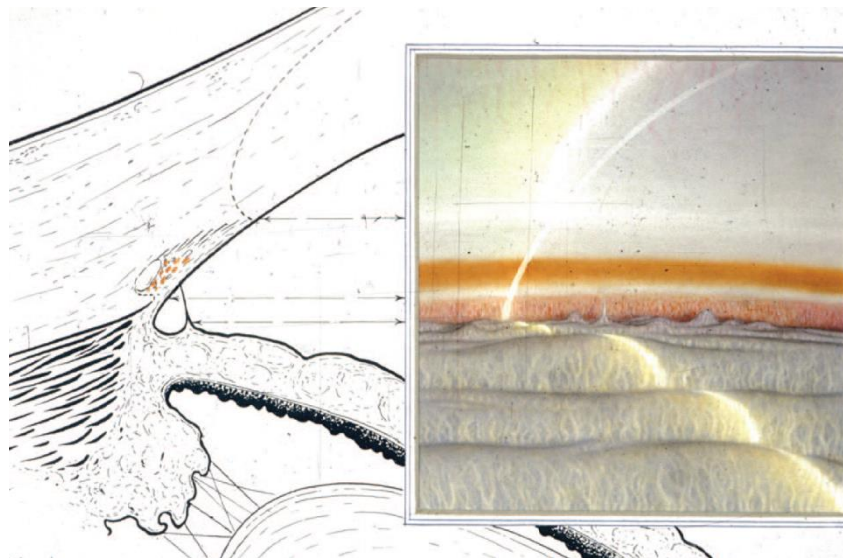


Figure 1 Normal angle structures: Structures visible from iris root are: ciliary body, scleral spur, pigmented trabecular meshwork, non-pigmented trabecular meshwork, Schwalbe's line. Courtesy of E Lee Allen, copyright the University of Iowa, used with permission.

Table 2 Shaffer Grading interpretation (adapted from Salmon<sup>21</sup>)

Shaffer angle	Grade	Structures Visible	Clinical interpretation
35-45°	4	Ciliary body	Closure impossible
25-35°	3	Scleral Spur	Closure impossible
20°	2	Pigmented TM	Closure possible but unlikely
10°	1	Non-Pigmented TM	Closure not inevitable but risk is high
0°	0	None	Closed

For the purposes of this study, an eye was defined as “occludable” if posterior trabecular meshwork was visible for less than 270 degrees, or in other words, if one or more quadrants was graded 0-1. An eye was graded as “open” if the posterior trabecular meshwork was visible in all four quadrants, or in other words, if all four quadrants were graded 2-4.<sup>15</sup> In this study, gonioscopy results at each visit were used as the reference standard against which van Herick method and AS-OCT were compared.

### Anterior Segment Optical Coherence Tomography Imaging

A spectral domain Topcon OCT-2000 (Topcon Europe Medical B.V, Netherlands, <http://www.topcon-medical.eu/eu>) operating in the Anterior Segment mode (wavelength of laser: 840nm) was used to image the ACA. A 3mm line scan size was selected, and the scan

count was set at 32. The scan zone was centred on the limbus, and the participant was asked to look at the fixation target. Two scans were taken and the scan with the best quality view of the scleral spur was selected for analysis. Scans of the nasal and temporal quadrant images were captured. The superior and inferior quadrants were not captured as the need to manipulate the lids when acquiring these images may lead to distortion of the angle.<sup>22</sup> AS-OCT was carried out in a darkened room (<5 lux).

The location of the scleral spur is an important anatomical landmark for the evaluation of the anterior chamber angle using AS-OCT. This is at the junction between the inner wall of the trabecular meshwork and the sclera. An eye was classified as “occludable” with AS-OCT if any iris contact was visible anterior to the position of the scleral spur for either the nasal or temporal image or both. The eye was graded as open if no iris contact was visible anterior to the scleral spur in either the nasal or temporal image. If the position of the scleral spur was too difficult to estimate for reasons relating to image quality, the angle was graded as “unsure”. Figure 2 shows an example of an open angle and an occludable angle.

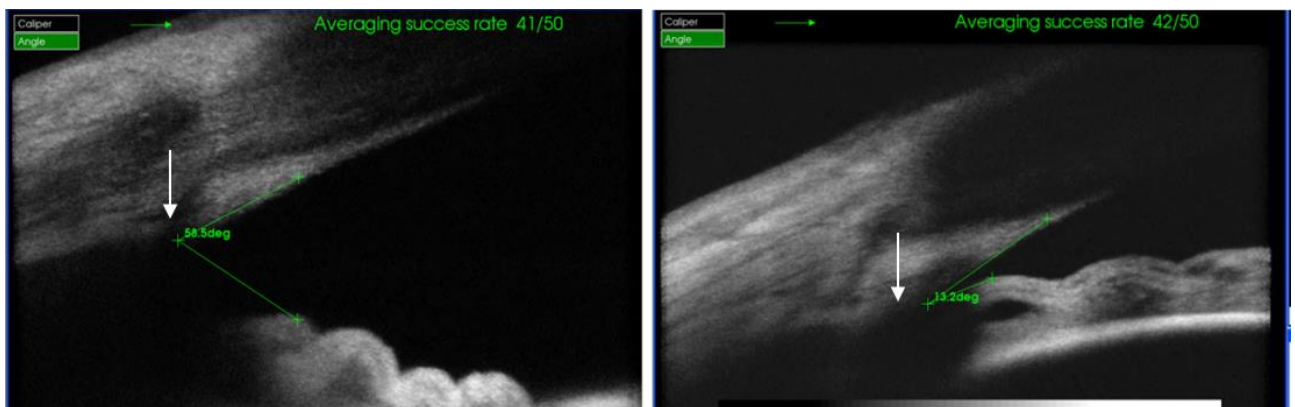


Figure 2 AS-OCT image capture and angle assessment, the white arrow indicates the position of the scleral spur. Left image - open angle. Right image - “occludable” angle.

### AS-OCT Images Masking Procedure

To avoid bias that could potentially be associated with one optometrist carrying out all three tests, the data were re-coded by a second optometrist (BJWE, an author) who randomised and anonymised the OCT images. A third optometrist (LRM, an author), who was masked as to the van Herick, gonioscopy and previous AS-OCT grades and was not involved in the data

collection or recoding, re-graded the OCT images. He was masked as to the identity of the participants, the clinic in which they were tested, and the visit from which the images were acquired.

Subjects who were found to have previously undiagnosed narrow angles with one or more of the three methods were referred appropriately for an ophthalmological opinion in line with normal optometric practice and local protocols.

## **Data Analysis**

One eye from each subject was selected at random for the analysis, provided both eyes were eligible for the study. For a given participant, data from the same eye were analysed on both visits.

Each test result allowed grading of the eye as “open”, “occludable” and in the case of AS-OCT, “unsure”. The intra-observer repeatability of each test at detecting eyes at risk of angle closure was made using cross tabulation of the data. Comparison of the van Herick method and AS-OCT with gonioscopy at detecting eyes at risk of angle closure was also determined using cross tabulation of the data. Statistical analysis was carried out using SPSS (version 18, SPSS Inc., Chicago, IL, <http://www-01.ibm.com/software/uk/analytics/spss/>).

The Cohen’s kappa statistic ( $\kappa$ ) was used to measure intra-observer repeatability of each test.<sup>23</sup> Sensitivity and specificity of the van Herick method and AS-OCT at classifying an angle as open or occludable, were calculated.<sup>6,12</sup> Ninety five percent confidence intervals were calculated using the Clopper-Pearson binomial probability confidence interval exact method.<sup>24</sup> The likelihood ratio was also calculated to assess the value of the van Herick method and AS-OCT in the identification of occludable ACAs.<sup>25</sup>

## Results

Eighty four subjects were recruited and eighty three subjects attended for both visits. Three subjects were unable to tolerate the gonioscopy test and their results were not included in the analysis. From the remaining participants (n = 80), 53 were female (66%), with the majority of the subjects Caucasian (88%); demographic features are outlined in Table 3.

Table 3 Demographic Features

Measure	Results
Age Mean(SD) Range	58.94 (10.03) years 40-80 years
Gender	53 Female 27 Male
Race Caucasian African descent Indian descent	70 6 4
Random Eye Allocation	47 Left; 33 Right

In four cases (two subjects at visit 1 and two different subjects at visit 2), the AS-OCT images were un-gradable due to difficulty in locating the scleral spur. The van Herick and gonioscopy results for these subjects were still included in the analysis. The number of eyes graded as occludable by each test, and the repeatability values (kappa) for each test are shown in Table 4.

Table 4 Number graded occludable by each test and the repeatability values with kappa “κ”

Test	Number found Occludable		Repeatability κ
	Visit 1	Visit 2	
Gonioscopy n=80	12 (15%)	13 (16%)	0.29
Van Herick n=80	17 (21%)	12 (15%)	0.54
AS-OCT n=76	12 (15%)	10 (13%)	0.47

Excluding the two subjects at each visit when AS-OCT grading was not possible, agreement in the classification grading in the remaining 78 subjects for the three tests was evaluated (see Figure 3 and Figure 4). For visit 1, four subjects were found to have narrow angles with all three methods, for visit 2 three subjects were found to have occludable angles with all three methods.

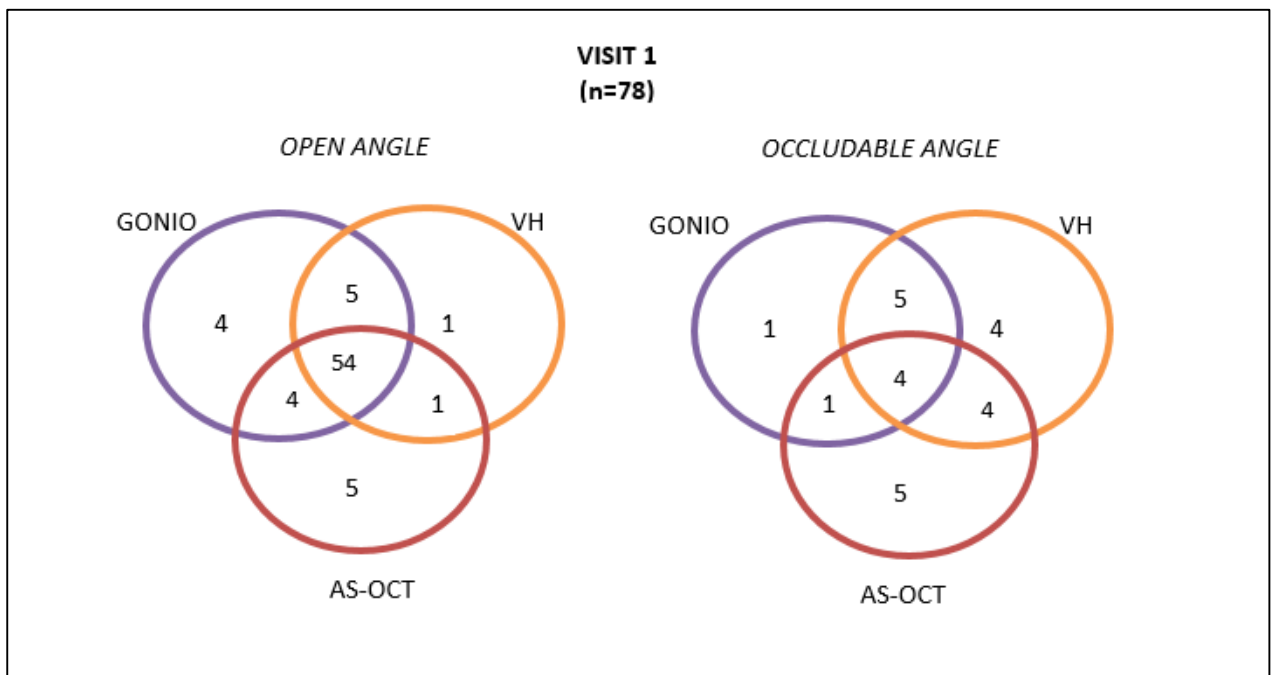


Figure 3 Number of eyes graded open or occludable for gonioscopy, van Herick method (VH) and AS-OCT at Visit 1.

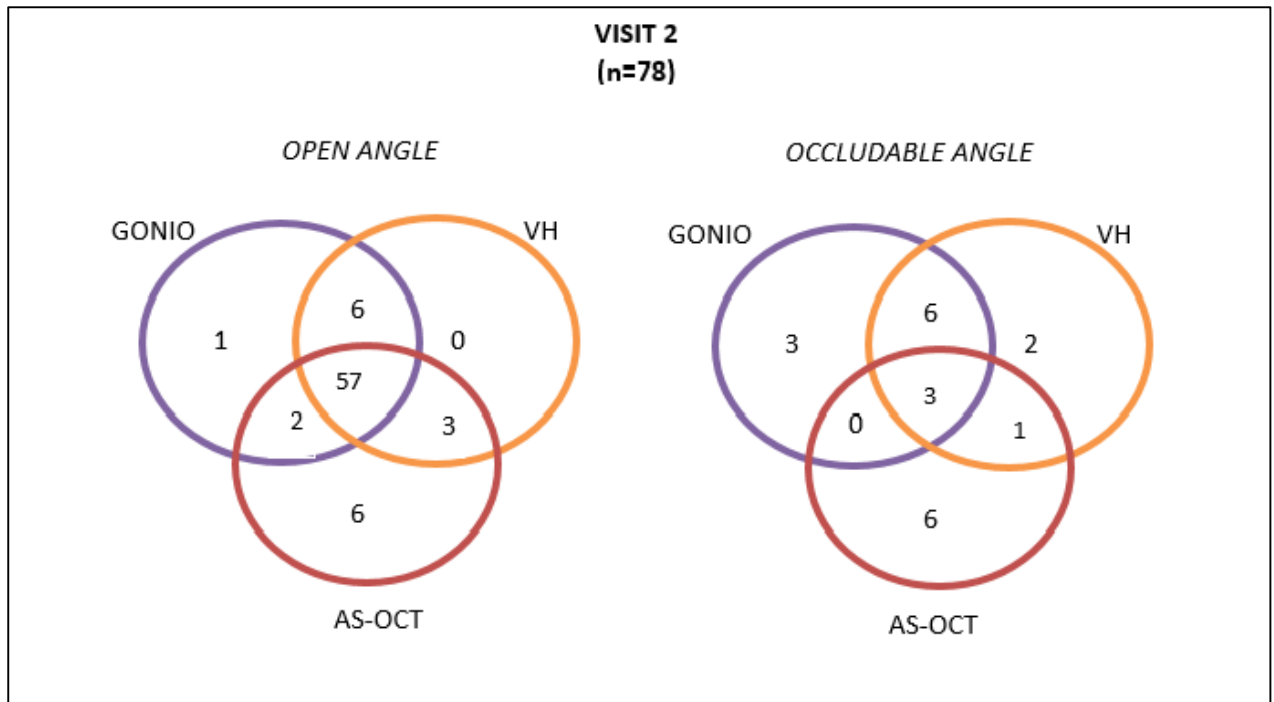


Figure 4 Number of eyes graded open or occludable for gonioscopy, van Herick method (VH) and AS-OCT at Visit 2.

The sensitivity, specificity and likelihood ratios of the van Herick method (n=80) and AS-OCT (n=78) were calculated and are shown in Table 5.

Table 5 Sensitivity and specificity of the Van Herick method and AS-OCT at each visit (CI=confidence Interval)

	<b>Sensitivity (%) (95% CI)</b>	<b>Specificity (%) (95% CI)</b>	<b>Likelihood Ratio</b>
Van Herick Visit 1 n=80	75 (43 - 94)	88 (78 - 95)	20.0
Van Herick Visit 2 n=80	69 (39 - 91)	96 (88 - 99)	27.1
AS-OCT Visit 1 n=78	46 (17 - 77)	87 (76 - 94)	6.8
AS-OCT Visit 2 n=78	25 (6 - 57)	89 (79 - 96)	2.3

## Discussion

One of the challenges healthcare provision increasingly faces is the rise in the ageing population. As a result of this rise, the prevalence of open angle glaucoma in England and Wales has been predicted to increase by 33% over the next twenty years,<sup>26</sup> with that of angle closure glaucoma expected to increase by 19% over the next decade.<sup>2</sup> In an attempt to reduce some of the impending burden on financial and human resources in the hospital eye service, optometrists are increasingly becoming involved in glaucoma shared care and referral refinement schemes within hospital and community settings.<sup>27</sup> Thus, they play an increasingly important part in the detection and management of glaucoma in the UK.<sup>28</sup> If such resources are to be used efficiently, it is important to assess the performance of practitioners and current tools used for diagnosis and management so that appropriate recommendations and interventions can be made, where necessary.

Anterior chamber angle assessment is an important part of the investigation of people at risk of glaucoma and ocular hypertension. NICE recommends the use of gonioscopy to confirm diagnosis of COAG or OHT.<sup>5</sup> The College of Optometrists guidelines highlight the importance of detecting narrow ACA.<sup>13</sup> Comparison of methods used to assess the ACA is important to clinicians, in order for them to identify the tools that will enable them to most accurately and efficiently manage patients with these conditions and those considered at risk. Although gonioscopy is the gold standard method of assessing the ACA, it is not routinely carried out by optometrists in UK community practice and while it is not considered a core competency by the General Optical Council its uptake in practice will likely remain low. Gonioscopy may also not be possible in certain countries where optometrist access to diagnostic drugs is restricted.<sup>3</sup> Thus, investigation of the relative utility of gonioscopy and more commonly used methods of assessing the ACA is important.

In this study, we have investigated the repeatability of gonioscopy, van Herick method and AS-OCT, and investigated the sensitivity and specificity of van Herick method and AS-OCT in the detection of eyes at risk of PACG within a community optometry setting. We found that



the intra-observer repeatability for assessing the ACA appears to be better for both the van Herick method and AS-OCT than for gonioscopy. Gonioscopy is a highly subjective test<sup>29</sup> and various factors may explain the variability in results. Gonioscopy involves direct contact with the eye and inadvertent pressure on the cornea may lead to distortion of the ACA, thereby affecting the visibility of the angle structures.<sup>15</sup> For example, results may be affected by a variation in the angle at which the lens is placed onto the cornea, or a difference in illumination settings at each visit. In addition, during gonioscopy, the examiner has to make a decision relatively quickly in order to minimise the discomfort to the patient, whereas the van Herick method and AS-OCT are much less invasive, and arguably, more time can be taken to grade the ACA using these methods, thereby potentially increasing repeatability. The fact that there are more structures to observe and consider in gonioscopy, compared with van Herick, may also contribute to its lower repeatability.

The van Herick method showed good sensitivity on the first and second visit respectively (visit 1: 75%, visit 2: 69%) and good specificity (visit 1: 88%, visit 2: 95%); AS-OCT shows poor sensitivity (visit 1: 46%, visit 2: 25%) but good specificity (visit 1: 87%, visit 2: 89%). Van Herick and AS-OCT would therefore appear to be good in the identification of patients with open angles, with the van Herick method more sensitive than AS-OCT at identifying occludable angles. Based on these results, if a practitioner were only to use an AS-OCT similar to the device used in this study, and no other ACA assessment method, this could result in a significant number of patients with an occludable angle being incorrectly identified as being open and not at risk of angle closure. This could have implications for this type of OCT device being used as a screening device for detecting angle closure.

The use of gonioscopy as the reference standard is, however, limited by the fact it has fair repeatability itself. The result of such fair repeatability would be that the apparent performance of the other techniques would fluctuate greatly between visits. In this study, the practitioner who performed gonioscopy was a highly-experienced hospital optometrist, typically performing gonioscopy up to ten times per week. Repeatability might therefore be expected to be poorer for novice users. Improved training and further professional qualifications have previously been associated with better performance with clinical techniques,<sup>30-32</sup> and it is reasonable to suggest that further clinical training in gonioscopy may

improve its utility in optometric practice, as well as in investigations of the utility of alternative forms of ACA assessment. Indeed, all three methods used here require subjective judgements, and a meticulous approach to testing procedures, as well as regular retraining, would likely improve and maintain performance.

The van Herick method led to the classification of a greater number of subjects as having occludable angles ( $n = 17$ ) than gonioscopy ( $n = 12$ ) at the first visit and one less than gonioscopy ( $n = 12$ ) at the second visit. As the van Herick method does not provide visualisation of the ACA structures, it might reasonably be expected to indicate more occludable angles than gonioscopy. We defined an eye as being occludable, with the van Herick method, if the grading was  $<25\%$ , a criterion that is commonly employed in clinical practice. If the criterion were changed to, say,  $<40\%$  (i.e. including those at  $25\%$ ), the number of eyes classified as having “occludable angles” with van Herick would increase. This would lead to an apparent increase in the sensitivity of the test, but would also reduce its specificity. Although the scales of measurement are very different in these techniques, it appears that the criteria for classifying angles as occludable with the van Herick method are more liberal (or that the criteria with gonioscopy are more conservative). It might be argued therefore that the relationship between the clinical criteria for classifying angles as occludable or open, with different methods of assessment, require further investigation.

For AS-OCT, the location of the scleral spur is used to determine if an angle is open or occludable. There were four cases where AS-OCT images were un-gradable due to difficulty in locating the scleral spur. Two of these cases were classified as occludable with gonioscopy, but all four were reported open with the van Herick method. One might speculate that it is more difficult to view the scleral spur in those eyes with a narrow angles with this type of AS-OCT. Reviewing the images for those subjects whose angles were reported to be occludable by gonioscopy but open with AS-OCT, it is possible that the margin of error around the estimated position of the scleral spur may have been greater than for the subjects with open angles. This may also partly explain the poor sensitivity of AS-OCT.

In our study, we used a spectral domain OCT, with a 840nm laser (Topcon 3D OCT-2000) whereas a standalone anterior segment OCT, with a 1300nm laser, allows deeper penetration

of the anterior segment structures and therefore better visualisation of the scleral spur.<sup>4</sup> This could offer better clinical utility, however standalone anterior segment devices are not commonly used in UK community optometry practice at the present time.

Intra-observer repeatability for gonioscopy in our study appears lower than that found in previous studies. In a study based at a glaucoma clinic in Singapore, the intra-observer repeatability of gonioscopy, performed on 20 eyes, was found to be very good ( $\kappa = 0.80 - 1.00$ ), when assessing all four quadrants,<sup>33</sup> whereas in the current study, the repeatability of gonioscopy was fair ( $\kappa = 0.29$ ). Direct comparison between the results should be made with caution. The size of the patient sample was smaller than in our study and our participants were relatively young (mean age 58.9 years) and mostly Caucasian (87.5%,  $p < 0.01$ ). The aforementioned study took place in Singapore where the prevalence of PACG is higher and the anterior segment dimensions tend to be different to those in European eyes.<sup>34</sup> The ophthalmologists involved in their study are likely to use gonioscopy more often than clinicians in the UK, as a result of encountering more patients with PACG.

Our findings for the sensitivity and specificity of van Herick method largely agree with those in other published literature. Foster et al.,<sup>8</sup> found sensitivity and specificity values for van Herick (also using gonioscopy as the reference standard) to be 84% (visit 1) and 86% (visit 2) in 1717 subjects in Mongolia, whereas the sensitivity and specificity values in the current study for van Herick method were 75% (visit 1), 69% (visit 2) and 88% (visit 1), 96% (visit 2) respectively. Park et al.,<sup>16</sup> found good agreement for van Herick in 93 eyes in Korea (sensitivity=92% and specificity=90% for the temporal quadrant).

Our measures of sensitivity and specificity of AS-OCT differ somewhat from those in other published literature. Nolan et al.<sup>15</sup>, using the Zeiss prototype AS-OCT, (1300nm laser), found excellent sensitivity (98%) but poor specificity (55%), with gonioscopy as the reference standard. We found poor sensitivity (46%, 25%) but good specificity (87%, 89%) for visits 1 and 2, respectively. A standalone AS-OCT, with a long wavelength laser, allows deeper penetration imaging and improved visualisation of the scleral spur, compared with a conventional OCT with at a shorter wavelength laser. It is possible that the lower sensitivity

of AS-OCT in the current study can be partly explained by the difficulty in visualising the scleral spur with a device employing a laser of such a short wavelength.

This study is limited by the possibility that results from the van Herick method may influence the judgement during gonioscopy. However, this sequence of testing is true to normal clinical practice where the clinician will carry out gonioscopy after assessing the angle with van Herick, and often a clinician may only carry out gonioscopy if the van Herick results suggest a narrow ACA. Image acquisition with the AS-OCT is mostly automated, and is therefore unlikely to have influenced the results of the other tests. For this method, it is the process of estimating the angle from the image which involves subjective judgement, and this was controlled for in the research by using a second grader, masked to the previous results.

The AS-OCT images captured provide information on the anterior chamber from a single axis scan only along the temporal and nasal quadrant whereas van Herick method and gonioscopy allow a wide angle view at each quadrant. On first consideration, this may be assumed to affect the direct comparability of the methods used, but we are comparing clinical classifications aided by these techniques, rather than the raw measurements, in order to evaluate their utility in clinical decision making. This clinical protocol was also adopted by other researchers.<sup>35</sup>

Most published research on comparing AS-OCT to gonioscopy is based on OCT devices designed specifically for investigating structures in the anterior segment. These devices use longer wavelength lasers (1300nm, compared with 840nm in the Topcon OCT), allowing deeper penetration imaging and improved visualisation of the scleral spur and ACA. These devices would therefore most likely enable more accurate ACA classifications than those found in our study. However, posterior segment OCT instruments such as the one used in this study are commonly used in ophthalmology clinics<sup>35</sup> and optometry practices in the UK, so our choice of instrument here enables a more realistic comparison of currently used clinical techniques.

In conclusion, this study provides important data on the utility of three commonly used methods of ACA assessment. The intra-observer repeatability of the van Herick method and AS-OCT at classifying an eye as open or occludable appears to be moderate and both methods appear to show better repeatability than gonioscopy. The van Herick method appears to have good sensitivity and specificity, whereas the AS-OCT method (using the Topcon 3D-2000 operating at 840nm) has poor sensitivity, yet high specificity. OCT instruments with longer wavelength lasers designed for anterior segment imaging may be superior to conventional OCTs for locating the scleral spur and making a more accurate classification of the ACA. Based on our findings, the van Herick technique may be preferable to using anterior segment OCT in clinical practice, at the present time, when investigating PACG.

## REFERENCES

1. Quigley HA & Broman AT. The number of people with glaucoma worldwide in 2010 and 2020. *Br J Ophthalmol* 2006; 90(3): 262–7.
2. Day AC, Baio G, Gazzard G et al. The prevalence of primary angle closure glaucoma in European derived populations: a systematic review. *Br J Ophthalmol* 2012; 96(9): 1162–7.
3. Gispets J, Cardona G, Verdú M & Tomàs N. Sources of variability of the van Herick technique for anterior angle estimation. *Clin Exp Optom* 2014; 97(2): 147-51.
4. Friedman DS & He M. Anterior chamber angle assessment techniques. *Surv Ophthalmol* 2008; 53(3): 250–73.
5. NICE. Glaucoma Diagnosis and Management of Chronic Open Angle Glaucoma and Ocular Hypertension. NICE Clinical Guideline 85. <http://www.guidance.nice.org.uk/CG85/Guidance/pdf/English>. 2009, accessed 06/12/2009.
6. National Health and Medical Research Council (Australia). NHMRC guidelines for the screening, prognosis, diagnosis, management and prevention of glaucoma. Australia 2010, [https://www.nhmrc.gov.au/files\\_nhmrc](https://www.nhmrc.gov.au/files_nhmrc), accessed 01/09/2014.

7. American Optometric Association (AOA). Care of the Patient with Open Angle Glaucoma. St. Louis: AOA, 2011, <http://www.aoa.org/documents/optometrists/CPG-9.pdf>, accessed 03/07/2014.
8. Foster PJ, Devereux JG, Alsbirk PH et al. Detection of gonioscopically occludable angles and primary angle closure glaucoma by estimation of limbal chamber depth in Asians: modified grading scheme. *Br J Ophthalmol* 2000; 84(2): 186–92.
9. Lavanya R, Foster PJ, Sakata LM, et al. Screening for narrow angles in the Singapore population: evaluation of new noncontact screening methods. *Ophthalmology* 2008;115(10): 1720–1727, 1727.e1–2.
10. General Optical Council. Optometry Stage 2 Core Competencies, 2011. [http://www.optical.org/en/Standards/Standards\\_in\\_competence.cfm](http://www.optical.org/en/Standards/Standards_in_competence.cfm), accessed 09/05/2014.
11. Dabasia, P. L., Edgar, D. F., Garway-Heath, D. F. & Lawrenson, J. G. A survey of current and anticipated use of standard and specialist equipment by UK optometrists. *Ophthalmic Physiol Opt* 2014; 34, 592–613.
12. Jamous KF, Kalloniatis M, Hayen A, Mitchell P, Stapleton FJ & Zangerl B. Application of clinical techniques relevant for glaucoma assessment by optometrists: concordance with guidelines. *Ophthalmic Physiol Opt* 2014; 34: 580–591.
13. College of Optometrists. Examining the patient at risk of glaucoma. <http://www.college-optometrists.org/en/utilities/document-summary.cfm/docid>, accessed 06.09.13.
14. Brezinski M & Fujimoto J. Optical coherence tomography: high-resolution imaging in non transparent tissue. *IEEE J Sel Top Quantum Electron* 1999; 5: 1185–92.
15. Nolan WP, See JL, Chew PTK et al. Detection of primary angle closure using anterior segment optical coherence tomography in Asian eyes. *Ophthalmology* 2007; 114(1): 33–9.
16. Park SB, Sung KR, Kang SY, Jo JW, Lee KS, & Kook MS. Assessment of narrow angles by gonioscopy, Van Herick method and anterior segment optical coherence tomography. *Jpn J Ophthalmol* 2011; 55(4): 343–50.
17. Kotecha A, White E, Schlottmann PG & Garway-Heath DF. Intraocular pressure measurement precision with the Goldmann applanation, dynamic contour, and ocular response analyzer tonometers. *Ophthalmology* 2010; 117(4): 730–7.

18. Bland JM & Altman DG. Statistical methods for assessing agreement between two methods of clinical measurement. *Lancet* 1986; 1(8476): 307–10.
19. Van Herick W, Shaffer RN & Schwartz A. Estimation of width of angle of anterior chamber. Incidence and significance of the narrow angle. *Am J Ophthalmol* 1969; 68(4): 626–9.
20. Shaffer RN. Primary glaucomas. *Gonioscopy, ophthalmology and perimetry. Trans Am Acad Ophthalmol Otolaryngol* 1960; 64: 112-27.
21. Salmon JF. Gonioscopy. In: *Glaucoma Volume 1: Medical Diagnosis and Therapy* (Shaarawy T, Sherwood MB, Crowston JG & Hitching RA) 1<sup>st</sup> edition. Elsevier: London; 2009. p. 173–83.
22. Sakata LM, Lavanya R, Friedman DS et al. Comparison of gonioscopy and anterior segment ocular coherence tomography in detecting angle closure in different quadrants of the anterior chamber angle. *Ophthalmology* 2008; 115(5): 769–74.
23. Fleiss JL. The measurement of interrater agreement. In: *Statistical methods for rates and proportions.* (Fleiss JL) 2<sup>nd</sup> edition, Wiley: New York, 1981; pp. 212-236.
24. Clopper CJ & Pearson ES. The Use of Confidence or Fiducial Limits Illustrated in the Case of the Binomial. *Biometrika* 1934; 26(4): 404–13.
25. Altman DG. Some common problems in medical research. In: *Practical Statistics for Medical Research.* 1<sup>st</sup> Edition (Altman DG) Chapman and Hall/CRC: Boca Raton, 1991; pp. 396-439
26. Tuck MW & Crick RP. The projected increase in glaucoma due to an ageing population. *Ophthalmic Physiol Opt* 2003; 23(2): 175–9.
27. Marks, JR, Harding, AK, Harper, RA et al. Agreement between specially trained and accredited optometrists and glaucoma specialist consultant ophthalmologists in their management of glaucoma patients. *Eye* 2012; 26 (6): 853–861.
28. Bell RW & O'Brien C. Accuracy of referral to a glaucoma clinic. *Ophthalmic Physiol Opt* 1997; 17(1): 7–11.
29. See JLS. Imaging of the anterior segment in glaucoma. *Clin Experiment Ophthalmol* 2009; 37(5): 506–13.
30. Hadwin SE, Redmond T, Garway-Heath D et al. Assessment of optic disc photographs for glaucoma by UK optometrists: the Moorfields Optic Disc Assessment Study (MODAS). *Ophthalmic Physiol Opt* 2013; 33(5):618-24

31. Theodossiades J, Murdoch I & Cousens S. Glaucoma case finding: a cluster-randomised intervention trial. *Eye* 2004; 18, 483–490.
32. Patel UDM, Murdoch I & Theodossiades J. Glaucoma detection in the community: does ongoing training of optometrists have a lasting effect? *Eye* 2006; 20, 591–594.
33. Sakata LM, Wong TTL, Wong H-T et al. Comparison of Visante and slit-lamp anterior segment optical coherence tomography in imaging the anterior chamber angle. *Eye* 2010; 24(4): 578–87.
34. Wang YE, Li Y, Wang D, He M, Lin S. Comparison of factors associated with occludable angle between american Caucasians and ethnic Chinese. *Invest Ophthalmol Vis Sci* 2013; 54(12): 7717–23.
35. Kalev-Landoy M, Day AC, Cordeiro MF & Migdal C. Optical coherence tomography in anterior segment imaging. *Acta Ophthalmol Scand* 2007; 85(4): 427–30.