



City Research Online

City, University of London Institutional Repository

Citation: Cox, C. L., Gibbons, H., Evans, P., Withers, T. & Titmus, K. (2011). HLA-B27 Positivity: associated health implications. *International Journal of Ophthalmic Practice*, 2(1), pp. 39-44.

This is the unspecified version of the paper.

This version of the publication may differ from the final published version.

Permanent repository link: <https://openaccess.city.ac.uk/id/eprint/2348/>

Link to published version:

Copyright: City Research Online aims to make research outputs of City, University of London available to a wider audience. Copyright and Moral Rights remain with the author(s) and/or copyright holders. URLs from City Research Online may be freely distributed and linked to.

Reuse: Copies of full items can be used for personal research or study, educational, or not-for-profit purposes without prior permission or charge. Provided that the authors, title and full bibliographic details are credited, a hyperlink and/or URL is given for the original metadata page and the content is not changed in any way.

City Research Online:

<http://openaccess.city.ac.uk/>

publications@city.ac.uk

HLA-B27 Positivity: associated health implications

Title: HLA-B27 Positivity: associated health implications

Authors:

Carol L. Cox, PhD, MSc, MA Ed, P G Dip Ed, BSc (Hons), RN, FAHE
Professor of Nursing, Advanced Clinical Practice
Department of Applied Biological Sciences,
School of Community and Health Sciences, City University London and Nursing
Research Lead, Moorfields Eye Hospital NHS Foundation Trust, London
e-mail: c.l.cox@city.ac.uk
Telephone: 202-7040-5812

Helen Gibbons MSc, P G Dip Opth, BA (Hons), RGN
Research Practitioner
Department of Applied Biological Sciences
City University London and Moorfields Eye Hospital NHS Foundation Trust
London
e-mail: helen.gibbons.1@city.ac.uk

Patricia Evans, MSc, PGCE, BSc (Hons), ENB 346, RGN
Lecturer, School of Health and Social Care
University of Greenwich, London
e-mail: Patricia.evans@greenwich.ac.uk

Timothy P. Withers, MSc, BA (Hons), OND, RGN Senior Nurse, Practice
Development, Moorfields Eye Hospital NHS Foundation Trust, London
e-mail: tim.withers@moorfields.nhs.uk

Karen Titmuss, MSc, BSc (Hons) RGN, OND.
Senior Sister, Moorfields Community Eye Service,
Northwick Park Hospital, Watford Road, Harrow, HA1 3UJ
e-mail: Karen.titmuss@moorfields.nhs.uk

Correspondence

Carol L. Cox, PhD, MSc, MA Ed, P G Dip Ed, BSc (Hons), RN, FAHE
Professor of Nursing, Advanced Clinical Practice
School of Community and Health Sciences, City University
20 Bartholomew Close
London EC1A 7QN

Phone: 020-7040-5812
Fax: 020-7040-5709

Abstract

HLA-B27 positivity makes the onset of autoimmune diseases such as Uveitis, Ankylosing spondylitis and Crohn's more likely to occur. Ankylosing spondylitis and Crohn's disease are two types of HLA-B27 positive diseases that demonstrate a direct association with Uveitis. Although the possession of HLA-B27 positivity is not mandatory for autoimmune diseases such as Uveitis to occur HLA-B27 positivity not only makes it more likely but may modify the clinical picture in which a patient presents. In relation to assessment and diagnosis it is imperative that the medical history of patients is thoroughly examined to ensure pathological sequelae are appropriately treated. Nurses play an important role in assessing patients that have Uveitis and should suspect Ankylosing spondylitis or Crohn's disease may be present.

HLA-B27 Positivity

A diagnosis of HLA-B27 positivity is the commonest known aetiology associated with a number of systemic autoimmune inflammatory diseases (Jones, 2001; Cauli et al, 2002; Monnet et al, 2004; Levinson, 2005; Andrews and Lightman, 2008; Di Lorenzo, 2008; Cox et al, 2008, 2010). HLA-B27 positivity increases the likelihood of developing inflammatory bowel disease, Crohn's disease, ulcerative colitis, ankylosing spondylitis, Reiter's syndrome, psoriasis and psoriatic arthropathy (Cauli et al, 2002; Di Lorenzo, 2008). A prominent factor involving the axial skeleton tends to HLA-B27 associated arthropathy (Jones, 2001; Cauli et al, 2002). Uveitis is a sequelae frequently associated with the aforementioned autoimmune diseases.

Not all HLA-B27 positive patients that have Uveitis will be aware that they have associated systemic disease. In addition, patients who are HLA-B27 positive who present with these autoimmune diseases may be unaware they are predisposed to the development of Uveitis. Early identification of HLA-B27 positive diseases; particularly as it relates to the arthropathies is essential as early treatment can affect long-term outcome. The predisposition toward HLA-B27 positivity is evident in some family groups with a ratio of male to female 1.5:1. In relation to Uveitis, it has been noted that 19 – 88% have this HLA phenotype depending on the population studied (Di Lorenzo, 2008; Cox et al 2008, 2010). Although there are difficulties in studying immunogenetics in Uveitis because of the small number of patients and families with the disease some progress is being made in relation to HLA-B27 associated Uveitis (Levinson, 2005).

Immunogenetics

HLA-B27 Positivity: associated health implications

In 1972, the first human leukocyte antigen (HLA) haplotype association with inflammatory disease was identified in which the correlation was made between HLA-B27 and ankylosing spondylitis (Di Lorenzo, 2008). Since 1972 a number of studies have linked the human leukocyte antigen (HLA) to other inflammatory diseases such as Crohn's disease. The majority of studies associated with Uveitis have described the human leukocyte antigen (HLA) association (Levinson, 2005; Di Lorenzo, 2008). Of patients diagnosed with Uveitis, as much as 50 - 60% may be HLA-B27 positive (Di Lorenzo, 2008). An individual's predisposition to development of disease and associated sequelae can be linked to a gene. The predictive positivity of an allele known to confer risk for disease in relation to a blood relative of a patient with Uveitis has not as yet been formally established, however research into families with HLA-B27 associated Uveitis may provide some useful guidelines that can be used to advise patients and their families about Uveitis and associated sequelae (Jones, 2001; Levinson, 2005; Di Lorenzo, 2008).

The HLA genes are found on chromosome 6 in the region that has become known as the major histocompatibility complex (MHC) of the human. Although the MHC contains many genes involved in the immune system, the gene products that are primarily responsible for an immune response are known as the human leukocyte antigens. They are characterised by evaluating an individual's serologic reactivity to allogenic leukocytes. Of particular note is that the HLA genes are consistently inherited together from either the maternal or paternal chromosome (Levinson, 2005; Cox et al, 2010). A haplotype can only be determined with certainty by family studies.

The HLA system has been linked with disease for over 30 years (Levinson, 2005). However the precise role of HLA molecules in disease pathogenesis such as Crohn's and Uveitis is still not well established (Levinson, 2005; Kanski, 2007; Di Lorenzo, 2008). It has been noted that microbial pathogens may play a more direct role in diseases that are considered due to autoimmunity including HLA associated Uveitis. For example, in at least a part of the autoimmune process, it is a result of a loss of tolerance to self antigens caused by exposure to pathogens which triggers ocular inflammation (Levinson, 2005). Self antigens are protective mechanisms that will occasionally fail for a variety of reasons, any one of which or combination therein leads to an autoimmune disease. For example, the pathogen may share some antigenic features with the patient such that an immune response against the foreign antigen also causes damage to the patient's cells that have a similar antigen (Jones, 2001).

Uveitis and its Causes

Uveitis can be caused by a number of autoimmune diseases including rheumatoid arthritis and ankylosing spondylitis as well as infection and exposure to toxins (DoH, 2006; Di Lorenzo, 2008). However, in many cases the cause

HLA-B27 Positivity: associated health implications

remains unknown (DoH, 2006). Uveitis is an inflammation of the uvea (Monnet et al, 2004; DoH, 2006). The uveal tract consists of three distinct sections, which have some similar and some individual features. These sections are the iris, the ciliary body and the choroid. One common feature of the three parts of the uveal tract is that they contain the main arterial and venous supply to the inner eye as well as containing pigment. Anatomically, Uveitis is classified into either anterior, intermediate, posterior or panuveitis (Andrews and Lightman, 2008; Kanski, 2010).

The blood vessels supplying the choroid/retina and iris are unique in that the junctions between the endothelium cells of the capillaries do not allow larger molecules to pass through (Forrester et al, 1999). This provides a physical barrier between the local blood vessels and the innermost parts of the globe. This barrier prevents the blood cells (lymphocytes and erythrocytes) from entering the eye where they would interfere with the transparency of the aqueous and the vitreous. It is known as the blood eye barrier and is similar to the blood brain barrier.

During the inflammatory response this barrier is compromised and can result in blood cells collecting in either the anterior or posterior segment. The presence of lymphocytes (white blood cells and other protein) in the anterior or posterior segments of the eye (known as 'cells and flare') is almost pathonemonic for the condition. The accumulation of cells and other protein causes a decrease in vision experienced by patients during acute attacks of Uveitis.

The most common form of Uveitis is acute anterior Uveitis (AAU), which involves inflammation in the front part of the eye. This form of Uveitis is usually limited to the iris and ciliary body. This condition is often called iritis (inflammation of the iris). It may typically affect only one eye but can be present in both eyes at the same time and has been found to be most common in young and middle-aged people. A history of an autoimmune disease is a risk factor and must always be taken into consideration during assessment. HLA-B27 associated AAU accounts for 18 – 32% of all cases of anterior Uveitis in Western countries and 6 – 13% of all cases of anterior Uveitis in Asia (Di Lorenzo, 2008).

Another form of Uveitis is pars planitis; also termed peripheral Uveitis. Pars planitis is inflammation of the pars plana, a narrow area between the iris and the choroid. Pars planitis usually occurs in young men, age 20 to 40 and is generally not associated with any other disease. However, there have been a few case reports of an association with Crohn's disease (Kanski, 2007, 2010). Some experts suggest a possible association with multiple sclerosis and sarcoidosis as well (Zimmerman, 2004). For this reason, these experts recommend that those over 25 years of age diagnosed with pars planitis receive an MRI of their brain and spine (DoH, 2006; Kanski, 2009, 2010).

HLA-B27 Positivity: associated health implications

Posterior Uveitis affects the posterior segment of the eye and may include inflammation of the retina as well as the choroid. This is called choroiditis. If the adjacent retina is also involved it is called chorioretinitis. Anterior, intermediate and posterior Uveitis may follow a systemic infection such as a campylobacter infection or occur in association with an autoimmune disease such as Ankylosing spondylitis or Crohn's disease.

In posterior Uveitis the inflammation causes spotty areas of scarring on the choroid and retina that result in areas of vision loss. The degree of vision loss depends on the amount and location of scarring. If the central part of the retina, called the macula, is involved, central vision becomes impaired. Uveitis can be associated with any of the disorders shown in Table 1.

- Chlamydial infection
- Bacillary dysentery (Gram-negative organisms including Shigella, Salmonella, Campylobacter, Klebsiella and Yersinia species.)
- Toxoplasmosis
- Tuberculosis
- Sarcoidosis
- Syphilis
- AIDS
- CMV retinitis or other cytomegalovirus infection
- Trauma
- Ulcerative colitis
- Kawasaki disease
- Herpes zoster infection
- Ankylosing spondylitis
- Beçhet's syndrome
- Psoriasis
- Reiter's syndrome

Table 1 Uveitis Associated Disorders

Signs and Symptoms of Uveitis

Symptoms of Uveitis depend on the site of inflammation and whether it is acute or chronic. Chronic Uveitis may be asymptomatic and only discovered on routine examination.

AAU accounts for approximately 75% of all cases of intraocular inflammation (Andrews and Lightman, 2008). AAU usually runs a short course of between 4 to 12 weeks (Kanski, 2007; Di Lorenzo, 2008). It has a tendency to affect the same eye especially in patients that are HLA-B27 positive however it is known to affect both eyes. AAU classically presents as a triad of pain, redness and photophobia. Pain can vary from mild to severe and is thought to be due to iris and ciliary body

HLA-B27 Positivity: associated health implications

spasm. Conjunctival injection may be present in the form of a ciliary flush which is redness around the limbus of the cornea. Vision may be blurred due to inflammatory cells in the anterior chamber and reduced ability to accommodate the lens for near vision. Symptoms evident in AAU are shown in Table 2.

Ocular manifestations may include:

- fine keratitic precipitates on the endothelium (Di Lorenzo, 2008).
- hypopyon which will be seen on detailed examination with a slit lamp (Andrews and Lightman, 2008).
- anterior chamber inflammation with an accumulation of cells and fibrinous exudate and synchiae (adhesions between the posterior iris and anterior lens capsule).

Generally complications of AAU include cataract, glaucoma, hypotony and cystoid macular oedema (Kanski, 2007; Di Lorenzo, 2008). Symptoms may develop rapidly and early attention of an ophthalmologist is critical in treating the disorder (DoH, 2006; Kanski, 2007; Cox et al, 2008, 2010).

- | |
|--|
| <ul style="list-style-type: none">• Redness of the eye• Blurred vision• Photophobia (sensitivity to light)• Dark, floating spots in the vision• Eye pain |
|--|

Table 2 Symptoms Evident in Acute Anterior Uveitis (AAU)

Medical Management

Examinations and Tests

A comprehensive ocular and systemic medical history, including family history, is essential. The history will inform a decision to investigate and the choice of tests to be undertaken (Andrews and Lightman, 2008; Kanski 2010). In recurrent episodes laboratory tests to distinguish between uveitic entities associated with HLA-B27 and those which are not may be included. Confirmation of the HLA-B27 status in an otherwise fit and healthy person may spare further investigation (Andrews and Lightman, 2008; Kanski 2010). Whenever there is suspicion of an associated systemic disease, appropriate referral is required. Vision assessment and slit lamp eye examination are essential in formulating an accurate diagnosis. Any suspected case of Uveitis should be referred to an ophthalmologist within 24 hours (Andrews and Lightman, 2008; Kanski 2010).

Treatment

HLA-B27 Positivity: associated health implications

Medical management of AAU involves the use of topical or systemic corticosteroids and topical cycloplegics. Occasionally, in recalcitrant or noncompliant cases and when the posterior segment is also involved (panuveitis), subconjunctival injections of corticosteroid and Mydracaine No 2 will be used. Other immunosuppressive therapy may become necessary in refractory cases. Topical corticosteroids have been the mainstay of Uveitis therapy but should be used with caution and prudently due to their side effects such as cataract formation and glaucoma. The primary goal in managing the disease and minimising complications is the elimination of all inflammatory cells from the inner eye. However the minimum amount of corticosteroids necessary should be used to control inflammation whilst preventing complications due to the side effects associated with corticosteroid therapy.

Pain and photophobia caused by spasm of the iris muscle is relieved by cycloplegics. Cycloplegics also prevent the development of synechiae which are fibrinous adhesions between the iris and the lens which affects the movement of the iris. Short acting dilating drops such as 1% Cyclopentolate Hydrochloride or 1 % Tropicamide work well and are generally used. These medications allow for the rapid recovery of pupillary function once the medication is discontinued. Longer acting cycloplegics are sometimes prescribed such as 1% Atropine or 2% Homatropine in some refractory cases. Patients prefer to wear dark spectacles to block out glare caused by the inflammation and the dilating drops. Some cycloplegics paralyse the ciliary muscle and interfere with near vision. Patients must be reminded that the treated eye will have a larger pupil than the other and that their vision will be blurred.

In some cases inflammation continues to recur following weaning of steroids. In these instances, nonsteroidal anti-inflammatory medications (NSAIDS) may be prescribed. Use of NSAIDS requires regular monitoring of liver and kidney function. Patients should be cautioned that they may need added medication to protect against the development of stomach ulcers.

Intermediate and Posterior Uveitis and Panuveitis

Pars planitis is often painless and the only symptom the patient may be aware of is sudden onset of floaters in their vision. Vision will only be noticeably affected if there is associated oedema of the macula. There may be minimum signs of inflammation in the anterior segment of the eye. Pars planitis is treated with oral steroids or other medications to suppress the immune system.

Choroiditis (posterior Uveitis) and panuveitis require determination of the underlying cause, and treatment of the underlying disease. Symptoms include decreased vision, floaters and patchy vision. The underlying disease may be serious. Additional specialists in infectious disease or autoimmunity may be needed for such diseases as syphilis, tuberculosis, AIDS, sarcoidosis, or Behcet's syndrome.

HLA-B27 Positivity: associated health implications

For systemic infectious diseases, corticosteroids are often used along with antibiotic therapy. For autoimmune diseases, various forms of suppression of the immune system may be required. Classic AAU generally resolves completely when promptly and aggressively treated however in chronic anterior Uveitis (CAU) low level inflammation is ongoing requiring prolonged treatment with steroid eye drops which can lead to the development of cataract and glaucoma particularly when inadequately managed. In instances where additional immunosuppressive treatment is required, immunosuppressive chemotherapy medications or immunomodulatory therapy (IMT) may be implemented. Medications within the regimen include Methotrexate, CellCept, Imuran, Cytoxan, Leukeran and Cyclosporin. In all cases the medication prescribed should be that which has the least potential for side effects. The use of these medications requires regular blood monitoring to ensure that side effects do not develop.

Prognosis

Classic AAU will resolve completely when treated promptly and aggressively (DoH, 2006; Di Lorenzo, 2008; Cox et al, 2010; Kanski, 2010). However, relapses are common; particularly in cases in which the patient is HLA-B27 positive. In posterior uveitis, the inflammation may last from months to years and may cause permanent vision damage, even with treatment.

Possible Complications are shown in Table 3.

- Glaucoma
- Cataracts
- Fluid within the retina
- Retinal detachment
- Vision loss

Table 3 Complications Associated with Uveitis

Ankylosing Spondylitis

Ankylosing spondylitis is an autoimmune disease that typically affects males between the age of 20 – 40 that are HLA-B27 positive. These individuals are seronegative for the rheumatoid factor. Initial symptoms include early morning stiffness or lower back pain (aching). Symptoms improve with activity. In advanced cases, bony ankylosis causes fixed flexion of the spine and in some patients cardiovascular complications are evident. The primary cardiovascular complication is the development of aortic incompetence which is diagnosed with ECHO. Patients with this condition frequently have a soft systolic murmur that can be heard with a stethoscope under the left arm (Cox, 2010). In the female, Ankylosing spondylitis is generally more benign. In children, Ankylosing

HLA-B27 Positivity: associated health implications

spondylitis frequently presents with a peripheral lower limb arthropathy in which back pain is absent (Kanski, 2007). Some patients also have ulcerative colitis or Crohn's disease as well as episodes of AAU or chronic Uveitis.

Crohn's Disease

Crohn's disease is a HLA-B27 positive disease which is chronic, relapsing and characterized by multifocal granulomas that generally involve the terminal ileum and anorectal components of the intestine (Kanski, 2007). Crohn's usually affects young adults and may be referred to as granulomatous ileocolitis, terminal ileitis or regional ileitis. Other sections of the gastrointestinal tract that may be involved include the oropharynx, oesophagus, stomach and jejunum. Manifestations of the disease include episcleritis, acute and or chronic Uveitis, low-grade fever, weight loss, arthritis, psoriasis, erythema nodosum, and liver disease. Ocular involvement occurs in approximately 10% of patients with Crohn's disease (Kanski, 2007). When Crohn's disease is associated with arthritis, the occurrence of AAU is increased by 2% - 30% (Kanski, 2007).

Case Study

Marion (pseudonym) experienced her first case of Uveitis at the age of 27. Marion had been painting her lounge window frames with oil based paint. After two days of using the paint Marion noticed a dull ache in her left eye. She thought nothing of it. 'Just a headache coming on from all of the paint fumes' Marion thought. The following morning Marion arose early. She noticed the ache was worse in her left eye. As she brushed some hair away from eyes her hand accidentally put pressure on her left eye. This action caused a severe pain to shoot to the back of her eye. Marion quickly turned on the light to see what had happened to her eye. The glare caused an excruciating pain to shoot to the back of her eye. She cried out in pain and switched off the light. Marion knew that she had to go to the hospital. However she could not maneuver in the dark to get dressed and she could not tolerate the light. The pain was making her physically ill. Feeling totally incapacitated, Marion went back to bed praying that the pain would ease. The pain only persisted and worsened. Finally, out of desperation, Marion called her father and asked him to take her to the hospital.

By the time Marion reached the hospital she could not see anything from her left eye. Upon history taking it emerged that her father and grandfather both suffered with what Marion thought might be a similar eye problem. They both had Uveitis and had been treated at the hospital episodically for many years. A blood test revealed that Marion was HLA-B27 positive.

Marion is 37 now. Over the years she has learned to manage her condition fairly well. Until the past two years Marion experienced 3 to 4 cases of Uveitis per year; only in her left eye. However for the past two years Marion has been experiencing Uveitis in both eyes and over the past 6 months has not been able

HLA-B27 Positivity: associated health implications

to stop using steroid drops for more than 2 to 3 weeks. Shortly after the drops are weaned off the Uveitis returns. A decision has been taken to administer intraocular steroid injections.

Over the years of being treated Marion has lost confidence in the nurses who triage her at the hospital. Marion would prefer not to be seen by the nurses. Marion always presents with photophobia and pain. However on each presentation, the nurses test her vision and shine a bright light in her eyes before she is given eye drops that decrease the pain. Marion would prefer to be given the medication that decreases the pain and stops her light sensitivity before they shine the light in her eyes. Marion also feels it is unnecessary to test her vision and that it is abusive to shine the light in her eyes. Marion would like to know why her vision is tested by the nurses when she has told them that she can't see. The doctors do not shine a light in her eyes before they have been 'dilated' and also don't test her vision. The doctors understand that she can't see and take her word for it. Marion also does not understand why the nurses look at her eyes with a slit lamp and check the pressure in her eyes when the doctors do the same thing. It seems like a waste of time having it done twice; especially when the nurses do not appear to do anything with the information they gain from checking her eyes.

Recently Marion mentioned to one of the doctors at the hospital that she has been losing weight. Marion is having frequent diarrhea and her stool has become bloody. Marion has been referred for Crohn's disease assessment.

Issues to Consider

Does Marion need any teaching about intraocular injections? If yes, who should provide this teaching?

Why do you think Marion has lost confidence in the nurses who triage her when she presents with Uveitis?

Should it be explained to Marion about why nurses test her vision and check her pupils with a bright light? If yes, who should provide this explanation?

Marion has been having recurrent bouts of Uveitis and has been losing weight. Should her HLA-B27 positivity have alerted clinicians to the potential of Marion developing Crohn's disease? If yes, who should have anticipated this development and referred Marion for early assessment?

Patient Behaviour

Patients with chronic Uveitis generally know when a flare-up is developing and may present with a complaint of 'grumbling pain' whilst demonstrating only

HLA-B27 Positivity: associated health implications

minimal signs on slit lamp examination. Subsequently it is possible for there to be a delay in the commencement of treatment as Uveitic patients frequently have minimal cells present on slit lamp examination when their condition is in remission. Alternatively some patients do not present early as they adopt a self diagnosis and treatment approach with the consent of their ophthalmologist. These patients must ensure they are seen as early as possible to confirm diagnosis, monitor intraocular pressure and response to medications.

Ophthalmic Care Provided by the Nurse

Nurses in many eye hospitals independently manage emergency care for patients that have Uveitis ('see and treat'). In relation to AAU there are issues about access to timely and appropriate care, prescribing treatment and referral. In Primary Care, nurses will see patients that have suspected Uveitis. Nurses managing such patients need to regard the red eye with a high note of caution and refer to an ophthalmic facility promptly if the patient has a photophobia or complains of an aching type pain in their eye. If eye pain or reduced vision is present, this condition is more urgent than if symptoms are very mild. Nurses must ensure that patients understand when AAU occurs this must be treated as an ophthalmic emergency.

Nurses engaged in assessment and diagnosis should question patients about symptoms reflecting autoimmune diseases when they are assessing associated Uveitis. In instances where an autoimmune disease like Ankylosing spondylitis or Crohn's disease is present or suspected, guidance must be provided in relation to the pre-disposition to uveitic conditions.

Conclusion

This article has presented a discussion associated with the causes, symptomatology and medical management of the HLA-B27 positive autoimmune disorder, Uveitis. Ankylosing spondylitis and Crohn's disease were considered as they are two types of HLA-B27 positive diseases that demonstrate a link to Uveitis. It was noted that patients who are HLA-B27 positive who present with Ankylosing spondylitis or Crohn's disease may be unaware they are predisposed to the development of Uveitis. It was further indicated that in relation to assessment and diagnosis it is essential that the medical history of the patient is thoroughly examined in order to ensure pathological sequelae is appropriately addressed.

References:

Andrews, R. and Lightman, S. (2008) Uveitis, in Jackson, T. (Ed), *Moorfields Manual of Ophthalmology*. London: Mosby Elsevier

HLA-B27 Positivity: associated health implications

Cauli, A., Dessoie, G., Fiorillo, M. et al. (2002) Increased levels of HLA-B27 expression in ankylosingspindylitis patients compared with healthy HLA-B27 positive subjects: a possible further susceptibility factor for the development of the disease. *Rheumatology* 41 (12):1375-1379

Cox, C., Evans, P., Withers, T. and Titmuss, K. (2008) The importance of gastrointestinal nursing being HLA-B27 aware, *Journal of Gastrointestinal Nursing*, 6 (9):32–40

Cox, C., Gibbons, H. Evans, P., Withers, T. and Titmuss, K. (2010) HLA-B27 Positivity, *Eye News Journal*, 16 (7):6–10

Cox, C. (2010) Examination of the Cardiovascular System, in Cox, C. (Ed), *Physical Assessment for Nurses*, 2nd edition. Oxford: Wiley-Blackwell

DoH (2006) Uveitis. Department of Health
<http://www.nlm.nih.gov/medlineplus/ency/article/001005.htm> (Accessed 22-11-10)

Di Lorenzo, A. (2008) HLA-B27 Syndromes. *Ophthalmology; Genetic Disorders, eMedicine*, 200 <http://www.emedicine.com/oph/topic721.htm> (Accessed 22-11-10)

Forrester, J., Dick, A., McMenamin, P. and Lee, W. (1999) *The Eye: Basic Sciences in Practice*. London: Saunders

Jones, N. (2001) *Uveitis: An Illustrated Manual*. London: Butterworth-Heinemann Ltd

Kanski, J. (2007) *Clinical Ophthalmology: A Systematic Approach*, 4th edition. London: Butterworths

Kanski, J. (2009) *Clinical Ophthalmology a Synopsis*, 2nd ed. London: Butterworth Heinemann Elsevier

Kanski, J. (2010) *Signs in Ophthalmology: Causes and Differential Diagnosis*. Edinburgh: Mosby Elsevier

Levinson, R. (2005) Immunogenetics of Ocular Inflammatory Disease, in Pleyer, U. and Mondino, B. (Eds) *Uveitis and Immunological Disorders*. New York: Springer

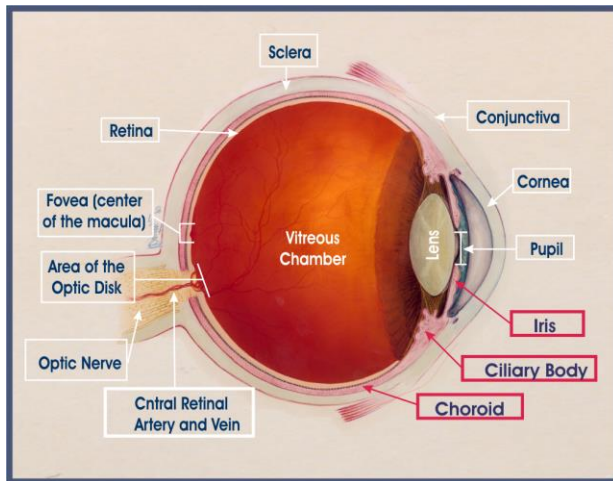
Monnet, D., Breban, M., Hurdy, C. et al. (2004) Ophthalmic findings and frequency of extraocular manifestations in patients with HLA-B27 Uveitis: a study of 175 cases. *Ophthalmology* 111 (4): 802-809

HLA-B27 Positivity: associated health implications

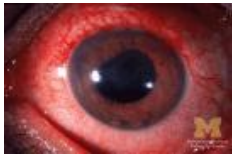
9. Zimmerman, P. (2004) Intermediate Uveitis: Pars planitis and other intermediate Uveitis, in Yannoff, M. and Duker, J., Augsburger, J., Azar, D. (Eds), *Ophthalmology*, (2nd Ed). London: Mosby

HLA-B27 Positivity: associated health implications

Anatomy of the Eye (We will need to get another drawing as this has been taken from the internet.)



Picture of Uveitis (We will need to get another picture as this has been taken from the internet.)



HLA-B27 Positivity: associated health implications

CPD Activity

<p>The possession of HLA-B27 positivity is not mandatory for autoimmune diseases such as Uveitis to occur however HLA-B27 positivity not only makes it more likely but may modify the clinical picture in which a patient presents.</p>	<p>Answer: True False</p>
<p>HLA-B27 positivity increases the likelihood of developing: a) inflammatory bowel disease b) Crohn's disease c) Ulcerative colitis d) Reiter's syndrome</p>	<p>Answer: B and C C and D A, B, and C A, B, C and D</p>
<p>All HLA-B27 positive patients that have Uveitis will be aware that they have associated systemic disease.</p>	<p>Answer: True False</p>
<p>The predisposition toward HLA-B27 positivity is evident in some family groups with a ratio of male to female 5:1.</p>	<p>Answer: True False</p>
<p>The predictive positivity of an allele known to confer risk for disease in relation to a blood relative of a patient with Uveitis has not as yet been formally established, however research into families with HLA-B27 associated Uveitis may provide some useful guidelines that can be used to advise patients and their families about Uveitis and associated sequelae</p>	<p>Answer: True False</p>
<p>Uveitis can be caused by a number of autoimmune diseases including: a) rheumatoid arthritis b) ankylosing spondylitis c) infection d) exposure to toxins</p>	<p>Answer: a, b, and c c and d a, b, c and d</p>
<p>AAU involves inflammation that is usually limited to the iris and ciliary body.</p>	<p>Answer: True</p>

HLA-B27 Positivity: associated health implications

	False
Pars planitis usually occurs in young men, age 20 to 40 and is has been associated Crohn's disease.	Answer: True False
Uveitis can be associated with: <input type="checkbox"/> a) _____ Chlamydial infection <input type="checkbox"/> b) _____ Bacillary dysentery (Gram-negative organisms including Shigella, Salmonella, Campylobacter, Klebsiella and Yersinia species.) <input type="checkbox"/> c) _____ Toxoplasmosis <input type="checkbox"/> d) _____ CMV retinitis or other cytomegalovirus infection <input type="checkbox"/> e) _____ Kawasaki disease <input type="checkbox"/> f) Herpes zoster infection	Answer: a through d b through f a through f c through f
AAU usually runs a short course of between 4 to 12 weeks and has a tendency to affect the same eye especially in patients that are HLA-B27 positive however it is known to affect both eyes.	Answer: True False
Symptoms evident in Uveitis include, redness of the eye, blurred vision, photophobia, dark floating spots in the vision and eye pain.	Answer: True False
In instances where additional immunosuppressive treatment is required to treat Uveitis, immunosuppressive immunomodulatory therapy is contraindicated.	Answer: True False

Formatted: Bullets and Numbering

CPD Answers

The possession of HLA-B27 positivity is not mandatory for autoimmune diseases such as Uveitis to occur however HLA-B27 positivity not only	True
--	------

HLA-B27 Positivity: associated health implications

<p>makes it more likely but may modify the clinical picture in which a patient presents.</p>	
<p>HLA-B27 positivity increases the likelihood of developing:</p> <ul style="list-style-type: none"> e) inflammatory bowel disease f) Crohn's disease g) Ulcerative colitis h) Reiter's syndrome 	A, B, C and D
<p>All HLA-B27 positive patients that have Uveitis will be aware that they have associated systemic disease.</p>	False
<p>The predisposition toward HLA-B27 positivity is evident in some family groups with a ratio of male to female 5:1.</p>	False
<p>The predictive positivity of an allele known to confer risk for disease in relation to a blood relative of a patient with Uveitis has not as yet been formally established, however research into families with HLA-B27 associated Uveitis may provide some useful guidelines that can be used to advise patients and their families about Uveitis and associated sequelae</p>	True
<p>Uveitis can be caused by a number of autoimmune diseases including:</p> <ul style="list-style-type: none"> e) rheumatoid arthritis f) ankylosing spondylitis g) infection <p>exposure to toxins</p>	a, b, c and d
<p>AAU involves inflammation that is usually limited to the iris and ciliary body.</p>	True
<p>Pars planitis usually occurs in young men, age 20 to 40 and is has been associated Crohn's disease.</p>	True
<p>Uveitis can be associated with:</p> <ul style="list-style-type: none"> ☐a) Chlamydial infection ☐b) Bacillary dysentery (Gram-negative organisms including Shigella, Salmonella, 	a through f

Formatted: Bullets and Numbering

HLA-B27 Positivity: associated health implications

<p>Campylobacter, Klebsiella and Yersinia species.)</p> <p><input type="checkbox"/>c) Toxoplasmosis</p> <p><input type="checkbox"/>d) CMV retinitis or other cytomegalovirus infection</p> <p><input type="checkbox"/>e) Kawasaki disease</p> <p><input type="checkbox"/>f) Herpes zoster infection</p>	
<p>AAU usually runs a short course of between 4 to 12 weeks and has a tendency to affect the same eye especially in patients that are HLA-B27 positive however it is known to affect both eyes.</p>	<p>True</p>
<p>Symptoms evident in Uveitis include, redness of the eye, blurred vision, photophobia, dark floating spots in the vision and eye pain.</p>	<p>True</p>
<p>In instances where additional immunosuppressive treatment is required to treat Uveitis, immunosuppressive immunomodulatory therapy is contraindicated.</p>	<p>False</p>