



City Research Online

City, University of London Institutional Repository

Citation: Keulen, S., Mariën, P., van Dun, K., D'aes, T., de Page, L., de Vroege, L., Van Schuerbeek, P., Raeymaekers, H., De Mey, J., Bastiaanse, R., et al (2021). Functional Foreign Accent Syndrome in suspected Conversion Disorder: A case study. *European Journal of Psychiatry*, 35(1), pp. 46-55. doi: 10.1016/j.ejpsy.2020.08.002

This is the accepted version of the paper.

This version of the publication may differ from the final published version.

Permanent repository link: <https://openaccess.city.ac.uk/id/eprint/25402/>

Link to published version: <https://doi.org/10.1016/j.ejpsy.2020.08.002>

Copyright: City Research Online aims to make research outputs of City, University of London available to a wider audience. Copyright and Moral Rights remain with the author(s) and/or copyright holders. URLs from City Research Online may be freely distributed and linked to.

Reuse: Copies of full items can be used for personal research or study, educational, or not-for-profit purposes without prior permission or charge. Provided that the authors, title and full bibliographic details are credited, a hyperlink and/or URL is given for the original metadata page and the content is not changed in any way.

Functional Foreign Accent Syndrome in suspected Conversion Disorder: a case study

Stefanie Keulen^{1,2}, Peter Mariën^{†1,3}, Kim van Dun⁴, Tine D'aes⁵, Louis de Page⁵, Lars de Vroeghe^{6,7}, Peter Van Schuerbeek⁸, Hubert Raeymaekers⁸, Johan De Mey⁸, Roelien Bastiaanse^{2,9}, Christina van der Feltz-Cornelis¹⁰, Philippe Paquier^{1,11,12}, Frank Van Overwalle¹³, Jo Verhoeven^{14,15}.

- 1. Centre for Linguistics (Clinical and Experimental Neurolinguistics), Vrije Universiteit Brussel, Belgium*
- 2. Center for Language and Cognition (CLCG), University of Groningen, The Netherlands*
- 3. ZNA Middelheim General Hospital (Antwerp), Belgium*
- 4. Department of Rehabilitation Sciences, Universiteit Hasselt, Belgium*
- 5. Department of Psychology, Vrije Universiteit Brussel, Belgium*
- 6. Clinical Centre of Excellence for Body, Mind and Health, GGz Breburg, The Netherlands*
- 7. Department Tranzo, Tilburg School of Behavioral and Social Sciences, Tilburg University, The Netherlands*
- 8. Department of radiology, UZ Brussels, Vrije Universiteit Brussel, Belgium*
- 9. Center for Language and Brain, National Research University Higher School of Economics, Moscow, Russia*
- 10. Department of Health Sciences, HYMS, YBRI. University of York, York, United Kingdom*
- 11. Department of Translational Neurosciences, University of Antwerp, Belgium*
- 12. Hôpital Erasme, Université Libre de Bruxelles, Belgium*
- 13. Experimental and Applied Psychology, Vrije Universiteit Brussel, Belgium*
- 14. Department of Language and Communication Science, City, University of London, United Kingdom*
- 15. Computational Linguistics and Psycholinguistics Research Center, University of Antwerp, Belgium*

Correspondence: Prof. Dr. Stefanie Keulen, Center for Clinical and Experimental Neurolinguistics, Centre for Linguistics (CLIN), Vrije Universiteit Brussel, Pleinlaan 2, 1050 Brussels, e-mail: stefanie.keulen@vub.be

Abstract

Background and objectives

We provide a case analysis for a 28-year-old, native Dutch-speaking lady who developed Foreign Accent Syndrome (FAS), a few weeks after falling down the staircase. In addition to FAS, which gave the impression she spoke with a German accent, German(-like) words and structures occurred. Speech symptoms were aggravated by increased stress, fatigue or emotional pressure, and this triggered jargon speech. It was hypothesized her FAS and jargon developed on a functional basis.

Methods

An in-depth analysis of the patient's medical background, neuropsychological and neurolinguistic tests and psychodiagnostic exams were done. The patient participated in an fMRI experiment. In a syllable repetition paradigm, motor speech activations were compared to those of healthy individuals, to see whether they were altered, which would be expected in case of a neurological etiology.

Results

Medical history disclosed prior traumatic experiences for which she sought help, but no neurological incidents. Repeated neuropsychological and neurolinguistic tests showed deficits in recent memory and executive functioning. The patient demonstrated great difficulties with picture naming. Clinically, language switching and mixing as well as recurring jargon speech was found. Formal psychodiagnostic tests did not identify a clear disorder, but psychodiagnostic interviews were consistent with a DSM-5 conversion disorder. The fMRI study demonstrated that speech network activations corresponded to those found in healthy participants.

Conclusion

The clinical neurolinguistic characteristics, outcome of the fMRI experiment, together with the clinical psychodiagnostic findings were strongly indicative for an underlying functional etiology for the FAS and jargon speech, presenting as symptoms of conversion disorder.

Keywords: foreign accent syndrome, FAS, language mixing, language switching, jargon, fMRI, speech, accent, functional disorder, conversion disorder.

1. Introduction

Healthy polyglot individuals automatically use the correct language depending on the communicative/pragmatic context. Language or code mixing (e.g. within utterance mixing of different languages) and switching (i.e. between languages or codes in alternating utterances) can occur naturally when speakers are in the process of acquiring a new language, such as in young bilingual or polyglot children (1, 2), but also in adolescent and adult language learners, in the course of the acquisition process, as mentioned by Duran (3). In all these cases, language mixing and switching can be consequence of failed neural suppression of the language that was not targeted. In terms of choice for one or the other language in bilinguals, Abutalebi and Green (4) use the term "lexical competition" to refer to an ongoing "competition" between the L1 and L2, and the related control phenomena that are decisive in the selection process. They (see also Abutalebi and Perani (5)), as well as Hernandez (6) mention that the efficiency of inhibition mechanisms depends on several factors including the degree of proficiency, age of acquisition and computational load of the languages. They are hypothesized to influence the strength of the induced plastic changes in the neural networks in the brain subserving for instance cognitive control mechanisms, including language inhibition. Failed inhibition in language learners will not be interpreted as "pathological": the errors can be explained within the dynamic framework of the above-mentioned parameters.

Pathological language mixing and switching typically refers to the process of blended language use in bilingual or polyglot aphasic patients (7,8,9). Some researchers have argued that the basal ganglia play a crucial role in both language switching and mixing (8,10), whereas others have argued that switching is mainly subserved by frontal circuits (11,12) and mixing by the temporo-parietal lobe (11).

Functional FAS in Conversion Disorder

Although typically described in the context of aphasia (e.g. 8), pathological language mixing and switching has been observed in a handful of cases with Foreign Accent Syndrome (FAS). One example is a 51-year-old woman with conversion disorder described by Verhoeven et al. (13) who switched between Dutch and French irregularly. Her Dutch lexicon, syntax and the pragmatics of her native tongue were all influenced by French. For instance, word order was French instead of Dutch. The case described by Reeves and Norton (14) (see also Reeves et al. (15)) suffered schizophrenia, and the patient switched from American English to a distinguished, formal register in *British* English whenever exacerbations were uncontrolled due to withdrawal from medication. In these cases, pathological language mixing and switching occurred within the context of an underlying psychiatric disorder. Nevertheless, these patients remained intelligible. So far, there has only been one report, by Gurnani and Horwitz (16), of a case in which a 39-year-old woman produced “non-sensical speech” in the context of a FAS (the acquired accent was qualified as “Ukrainian”, although the mother tongue was not reported).

Jargon speech is usually associated with acquired aphasia (e.g. 17,18). Rohrer et al. (18) state jargon can in that case be semantic (language devoid of content), phonemic (production of words phonemically related to the target) or neologistic in nature (words and nonwords, semantically and phonemically not related to the target word). In these cases, the jargon aphasia has been suggested to be caused by a resource limitation deficit, a comprehension deficit, a feedback or production deficit, or a verbal monitoring deficit depending on the specific case presentation (19). In contrast to "*schizophasia*" or the "meaningless mixture of words and phrases characteristic of advanced schizophrenia" (20, p. 201) that can wax and wane, patients suffering from jargon aphasia retain persistent expressive problems (18). The language disorder does not fluctuate and the neurological symptoms will demonstrate a more linear resolution in case of remission.

Functional FAS in Conversion Disorder

Here we present a detailed work-up of 28-year-old female patient who presented with a sudden change of accent, which from time-to-time evolved to an unintelligible phonological jargon, in the absence of structural neurological damage.

2. Case study

2.1. Medical history

The patient is a 28-year-old, monolingual female native speaker of Dutch from the Netherlands, with monolingual Dutch-speaking parents and an educational level of 13 years. At school, she studied English for five years, received one year of French and two years of German language instruction. She worked as an ancillary nurse in a hospital. Her medical antecedents consisted of asthma and migraine. There was no indication of alcohol or drug abuse. She had previously experienced two miscarriages and was in the 16th week of her first pregnancy when she developed FAS a few weeks after falling down a staircase (June, 2013). The fall did not impact the health of her child. Her proxies perceived her as a non-native speaker of Dutch, initially with a Turkish or Moroccan accent, later Belgian Dutch, the Dutch variant spoken in the northern part of Belgium.

Clinical neurological examination, laboratory tests and neuroradiological (MRI) investigations carried out after the fall were normal. A series of psychosocial stress factors were noted: the patient mentioned persistent emotional difficulties as a child after the death of her mother from a brain hemorrhage. She admitted to have suffered from this early loss for which she had been treated by a medical psychologist for a suspected post-traumatic stress disorder after her mother's death but could not remember the duration.

The patient consulted the hospital in November 2014, some six months after the fall, and complained about headaches, tension, stress, disoriented thoughts and behavior as well as attention difficulties. She mentioned that her accent was often perceived as

Functional FAS in Conversion Disorder

Belgian Dutch, French or German. Occasionally, language mixing occurred (German), especially when she was stressed and she “could not cope with the large number of external stimuli”. The impact of stressors was very clear during the intake interview. When speech-language therapists entered the consultation room to attend the session, the patient’s speech deteriorated significantly and FAS symptoms aggravated. She developed a Belgian Dutch accent, then started to mix German and Dutch words and expressions, e.g. "*Danke, danke sehr, dokter*" ("Thanks, many thanks, doctor").

She claimed that she had had no regular contact with speakers of Belgian Dutch. However, her sister-in-law was German. Following the accent change, she developed loose thoughts and visual hallucinations which lasted for an unspecified number of weeks. She mentioned that she had also suffered from severely disoriented behavior which arose for the first time approximately two weeks after the fall. This distraught behavior continued throughout her pregnancy, and according to the patient, it was the result of increased stress and severe anxiety which she related to the death of her mother at a young age. The patient’s husband volunteered the same information in a separate interview. These behaviors were highly egodystonic and provoked a fear of insanity, also referred to in the literature as “phrenophobia” (21). The patient mentioned that she had not benefitted from previous psychological therapy and that she had never received medication to cope with her symptoms. At the time the patient visited the neurology department she was implicated in a disability litigation.

After the development of the current symptoms, she tried to continue her work but she could not concentrate long enough to stay in the profession. At the time of consultation, the patient parented her daughter (1,5 years old) and managed the household. She mentioned that she was easily over-aroused physically. During a last contact with the patient in April 2020, she mentioned that cognitive-behavioral therapy

Functional FAS in Conversion Disorder (CBT), acceptance and commitment therapy helped her, though not to such extent that she had no more episodes of accent change or jargon, or that episodes were reduced in duration. However, she felt she was more in control of her life by having learnt to set and communicate her boundaries. The patient mentioned she now avoided crowded places, and that the stress she experienced put pressure on her relationship.

2.2. Neuropsychological investigations

Table 2.1.

Overview of the neuropsychological test results of the patient at four instances.

Neurocognitive tests	03/11/2014 (raw score or SS) SD or Pc	05/06/2015 (raw score or SS) SD or Pc	24/4/2016 (raw score or SS) SD or Pc	06/05/2016 (raw score or SS) SD or Pc	MEAN (\pm 1SD)
Intelligence					
WAIS-IV-NL					
Verbal comprehension	(83) -1.13 SD				100 (\pm 15)
Perceptual reasoning	(85) - 1 SD				100 (\pm 15)
Working memory	(92) - 0.53 SD			22	100 (\pm 15)
Processing speed	(84) - 1.07 SD			76	100 (\pm 15)
Total IQ	(81) - 1.27 SD				100 (\pm 15)
Memory					
WMS-R					
Attention	(94) -0.4 SD	(87) -0.9 SD	(95) -0.3 SD		100 (\pm 15)
Visual memory	(84) -1.1 SD	(104) +0.3 SD	(109) +0.6 SD		100 (\pm 15)
Verbal memory	(96) -0.3 SD	(76) -1.6 SD	(87) -0.9 SD		100 (\pm 15)
General memory	(91) -0.6 SD	(82) -1.2 SD	(92) -0.5 SD		100 (\pm 15)
Recent memory	(70) -2.0 SD	(76) -1.6 SD	(76) -1.6 SD		100 (\pm 15)
RBANS					
Immediate memory	(83) -1.1 SD			(83) -1.1 SD	100 (\pm 15)
Recent memory	(56) -2.9 SD			(52) -3.2 SD	100 (\pm 15)
RAVLT					
Total learning score				(30) pc 1	
Recall				(2) pc 2	
Recognition				(22/30)	

Functional FAS in Conversion Disorder

TOMM (memory malingering)		48/50		
Executive functioning and attention				
TMT A	(29'') pc 70	(36'') pc 14		
TMT B	(42'') pc >90	(67'') pc 46		
Stroop test: Card 1	(48'') pc 40	(66'') pc 1		
Stroop test: Card 2	(55'') pc 60	(79'') pc 1		
Stroop test: Card 3	(80'') pc 70	(107'') pc 58		
d2-test				
Tn	(393) -1.2 SD	(546) +0.8 SD		
Tn-E	(371) -1.3 SD	(519) -0.79 SD		
CP	(146) -1.5 SD	(211) +0.05 SD		
WCST	(6) +0.38 SD		5.58 (±1.1)	
RBANS	(97) -0.2 SD	(88) -0.8 SD	100 (±15)	
Verbal fluency	(70) -2.0 SD		60.2 (±21.28)	
Language				
BNT	(41/60) −3.19 SD	(44/60)-2.4 SD	(28/60) -6.7 SD	52.8 (±3.7)
RBANS	(108) +0.5 SD		(101) +0.1 SD	100 (±15)
Visuospatial skills				
RBANS	(100) ±0.0 SD	(96) -0.3 SD		100 (±15)
Language				
Aachener Aphasia Test (Dutch)				
Comprehension				
Auditory - Words	(24/30)			
Auditory - Sentences	(28/30)			
Reading - Words	(21/30)			
Reading - Sentences	(29/30)			
Token Test	(36/36)			

Legend: BNT= Boston Naming Test (22); CAT-NL= Comprehensive Aphasia Test-NL (23); Pc.= percentile; RBANS= Repeated Battery for the Assessment of Neuropsychological Status (24); RAVLT= Rey Auditory Verbal Learning Test (25); SD= standard deviation; SS= Scaled Score, TMT= Trail Making Test (26); TOMM= Test of Memory Malingering (27); WAIS-IV-NL= Wechsler Adult Intelligence Scale IV, Dutch

Functional FAS in Conversion Disorder
version (28); WCST= Wisconsin Card Sorting Test (29); WMS-R= Wechsler Memory
Scale Revised (30).

Overall, mnemonic capacities tested via the WMS-R remained stable over approximately 1,5 years, with relatively intact attention, and visual and verbal memory. Recent memory proved affected over three testing sessions. This was confirmed via testing on the R-BANS which showed severely impaired functioning. The patient scored remarkably worse on the TMT A & B and Stroop tasks (cards 1 to 3) during her fourth and last repeat neuropsychological investigation: whereas initially scores were largely within an acceptable range (except for Stroop card 2) in 2014, this was no longer the case in 2016. Scores on the d2-test (31), a measure of visual attention, concentration and inhibition, were (borderline) moderate in 2014. In terms of language assessment, visual naming (BNT) was severely impaired over three test sessions, with a very remarkable regression during the test session of April 2016, where she obtained only 28/60 (-6.7 SD). Errors (predominantly) consisted of neologistic (e.g. "escalator" was referred to as "wheel chair staircase"), semantic (e.g. "lion" instead of "sphinx") and visual (e.g. "branch" instead of "asparagus") mistakes. The CAT-NL revealed a weak performance on the oral picture description: grammar and syntax were severely impaired. During her last testing session, issues were hence very specifically situated in the area of recent memory, attention, executive functioning, and naming and narrative skills.

2.3. Psychodiagnostic examinations

In December 2014, the patient underwent a psychodiagnostic assessment in the neurolinguistics and neuropsychology department of the hospital where she was initially seen as a part of the work-up. The tests consisted of the Minnesota Multiphasic

Functional FAS in Conversion Disorder

Personality Inventory-2 (MMPI-2, 32), NEO-FFI (Neuroticism, Extraversion, Openness - Five Factor Inventory, 33), the Defense Style Questionnaire-60 (DSQ; 34), the Supernormality Scale (SS; 35), the Beck Depression Inventory-II (BDI; 36), the Depressive Experience Questionnaire (DEQ; 37), the List of Indeterminate Psychopathology (LIPP; 38), Rotter Incomplete Sentence Blanks (RISB; 39), as well as an exhaustive psychological examination (both individually and conjointly with her husband).

Her overall personality profile (MMPI, DSQ, DEQ) revealed a sensitive, people-pleasing, dependent personality without any indications for a psychotic structure or symptoms. On the contrary, there were more indications for a stable neurotic personality organization (40). The test results could not account for the psychotic behavior that had been noted in past. Malingering tests (the SS, LIPP and MMPI-2 validity indices) revealed a slight tendency for a naive positive self-presentation, but without significant effects on test results. The BDI-2, DSQ-60 and DEQ were presented twice (with a 2-week interval) to check for consistency in response patterns.

Individuals with similar profiles (Within Normal Limit, or "WNL"-profile with a 3-6-0 pattern) are described as normal individuals, experiencing "transient situational distress" (41). Their mood is described as stable and happy (as reflected in a BDI-2 total score of 3 out 63). The patient did no longer mention any cognitive issues herself, although these were formally identified in neurocognitive testing. Although these code-types are associated with reported transient psychotic symptoms, it remains unclear whether her low scores warrant this association. The profiles did not suggest a strong potential for somatization or for a conversion disorder. Nevertheless, clear indications were found for a dependent personality. Through analysis of quantitative tests results, projective tests (RISB) and the clinical examination, the neurotic personality organization proved to be arguably immature.

Functional FAS in Conversion Disorder

It is important to mention that the test results did not allow a clear interpretation. The face-to-face examination, however, was more informative. During the first interview, the accent was subtle, only slightly noticeable when technical or peripheral topics were discussed, but when the conversation touched upon affective topics, her accent and her speech distorted rapidly. It changed back to normal when less emotional issues were discussed. During the interviews, she was pleasant, polite and very open. Although she did not recognize any psychopathology, suffering or mental pain at first, she (through a discussion with her partner) recognized her tendency to occult, repress and split affective experience roughly, and nearly dissociate when negative feelings became too threatening. She appeared interested in the assessment and remained hopeful about its results. When the feedback was provided (the same day) her foreign accent returned almost immediately. By changing the topic of the conversation and the number of individuals present during the conversation (her partner, staff) - and hence varying the emotional pressure, cognitive load and fatigue - quantitative distortions in her accent could be triggered quite easily until a jargon-like speech remained. It took significantly longer for the accent to disappear again.

In 2015, the patient was examined again. The psychiatric evaluation yielded no signs of a depressive disorder, anxiety disorder or obsessive-compulsive disorder, and no symptoms of a post-traumatic disorder or dissociative disorder were found. Additional information revealed a very strained relationship with her stepmother following the death of her mother. Psychosomatically, a change of accent was very noticeable: it ranged from Belgian Dutch to (flawed) German. This accent changed as a result of increased fatigue. Therefore, a diagnosis of FAS seemed appropriate at the time of psychiatric evaluation.

Presentation was consistent with a DSM-5 (42) classification of “conversion disorder” with speech symptoms.

2.4. Phonetic description of speech

We recorded two spontaneous speech samples: one with accented spontaneous speech and one with (phonological) jargon. There are various aspects of the patient’s speech which could account for the perception of a German accent. As far as the fricatives are concerned, the patient sometimes articulated the Dutch alveolar fricatives (/s/ and /z/) as postalveolar /ʃ/ (eg. [zwarə] “heavy” is pronounced as [ʃwa:rə], [slapə] “to sleep” is pronounced as [ʃla:pə]). The occurrence of the voiceless postalveolar fricative as the first element in word-initial consonant clusters (e.g. [ʃwa:rə]) and in word-final position (e.g. [ɔləʃ]) is a feature of German, not Dutch. Another factor contributing to the perception of a German accent is the devoicing of the labiodental fricative /v/ to /f/ (e.g. [fɛɪl], “much”), the alveolar fricative /z/ to /s/ (e.g. [sɛɪnə], “his”) and the velar fricative /ɣ/ to /x/ (e.g. [xəvələ], “to fall + past tense”). Although the devoicing of fricatives is very common in Belgian Dutch (43) this feature is consistent with the perception of a German foreign accent.

In terms of the vowels, there are two relevant observations. First, the patient often adds *sjwa* to the end of words and this may change the Dutch word into a German word (e.g. Dutch [zɔn] becomes German [zɔnə], “sun”). Secondly, it should be pointed out that the pronunciation of the diphthong [ɛɪ] has an onset which is too posterior and too open so that it sounds like [ɑɪ] (e.g. [mɛɪn] becomes [maɪn], “mine”). This no doubt also contributes to the perception of a German accent.

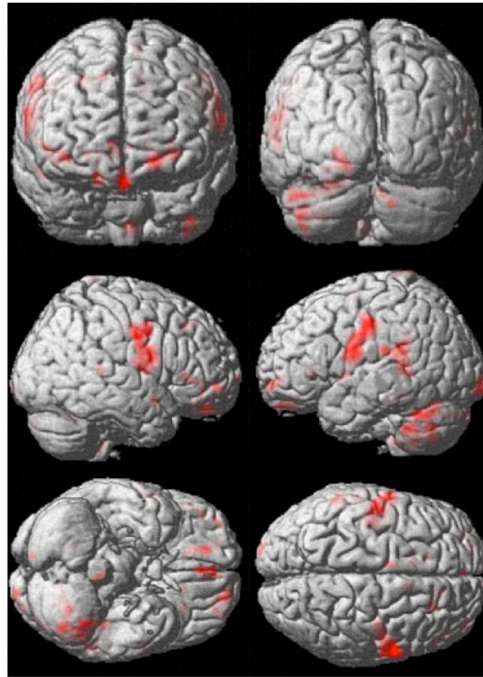
2.5 Functional MRI

To study the neurological substrates of the patient's speech, functional MRI (fMRI) was carried out. The protocol was adapted from Brendel et al. (44) and consisted of one 30-minute run during which three conditions were presented in pseudo-randomized order: "pa-ta-ka" (=planning), "ta-ta-ta" (=no planning), and a visual control condition without articulation (=baseline). All three conditions consisted of a 2-second information screen showing which task should be performed ("pa-ta-ka", "ta-ta-ta", no articulation), a 2-second preparatory visual cue (black cross in the center of a white screen) and a 4-second window consisting of 10 flickering crosses at 2.5 Hz, or a 1.6-second window consisting of 4 flickering crosses at 2.5Hz. The patient was asked to repeat the syllables "ta-ta-ta" or "pa-ta-ka" synchronously with the flickering cross. The first flicker was the "GO"-signal. The stimuli were presented to the patient on a screen. The patient received articulation training before scanning in order to minimize (mandibular) movement artefacts. Stimuli were programmed in E-Prime (Psychology Software Tools, 2016).

fMRI analyses contrasted the long speech conditions (3 times "pa-ta-ka" and "ta-ta-ta") with the visual control condition, analogous to the main analysis of Brendel et al. (44) (see appendix for acquisition specifications and analysis).

Figure 2.1.

Functional Magnetic Resonance Image (fMRI). Significant activation sites when LC > visual baseline. Significant clusters at uncorrected $p < 0.001$ and $\#voxels > 10$. All clusters with FWE-corrected $p > 0.05$ and a peak with FWE-corrected $p < 0.05$ are shown. Activation sites can further be consulted in **Table 2.2**.



Results indicated no significant anomalies (see Figure 2.1). Table 2.2 lists the most important clusters found in our patient. Most of the clusters (in **bold**) were also found in the healthy participants of Brendel et al. (44). The most important clusters in the sensorimotor cortex (SMC) and the supplementary motor area (SMA) were activated, together with the left insula and the left superior temporal gyrus (STG). These areas are principally involved in motor planning and programming as well as motor preparedness (esp. SMA). Smaller clusters in for example the basal ganglia (essential structures mediating speech execution, as well as exerting a control function) were not reproduced, probably due to statistical constraints in a single-patient fMRI study. In the cerebellum, only left-sided activation was found in lobule VI, and in Crus I, an area that is more related to motor preparedness. In this patient, the activation extended also to lobule VIII, the second cerebellar sensorimotor area, and to Crus II, which is strongly associated to language processing.

Apart from a stronger left-sided lateralisation in the cerebellum, it seems the speech activations appeared to be very comparable to what was seen in the subjects

Functional FAS in Conversion Disorder
without speech and language disorders who participated in the study of Brendel et al.
Hence, this further confirmed the hypothesis that this patient developed her speech
problems on a psychogenic basis.

Table 2.2.

Overview of activation sites in the speech network in the investigated patient during a
syllable-repetition task. Activation sites represent LC > visual baseline. Significant
clusters at uncorrected $p < 0.001$ and #voxels > 10. All clusters with FWE-corrected $p >$
0.05 and a peak with FWE-corrected $p < 0.05$ are listed.

Table 2.2.

Overview of activation sites in the speech network in the investigated patient during a
syllable-repetition task. Activation sites represent LC > visual baseline. Significant
clusters at uncorrected $p < 0.001$ and #voxels > 10. All clusters with FWE-corrected $p >$
0.05 and a peak with FWE-corrected $p < 0.05$ are listed.

Cluster		Peak		MNI coordinates {mm}			Area
p (FWE-corr)	#Voxels	p (FWE-corr)	Z	x	y	z	
0.000	312	0.000	Inf	-42	-18	39	L postcentral
		0.000	7.50	-60	-6	18	
		0.011	5.11	-48	-9	30	
0.000	273	0.000	7.09	45	-9	36	R BA6
		0.000	6.93	42	-12	39	
		0.000	6.53	60	3	21	
		0.001	5.51	51	-3	42	

Functional FAS in Conversion Disorder						
		0.003	5.35	54	-6	30
		0.014	5.06	63	0	9 R rolandic operculum
0.000	318	0.000	6.51	-39	-42	-45 L CB VIII
		0.000	6.16	-27	-60	-24 L CB VI
		0.001	5.58	-21	-69	-24
		0.003	5.33	-51	-57	-33 L Crus I
		0.004	5.31	-48	-66	-30
		0.005	5.25	-30	-60	-45
		0.014	5.07	-18	-63	-21
		0.015	5.05	-45	-66	-42 L Crus II
		0.019	5.00	-42	-54	-30
		0.027	4.94	-42	-66	-51
		0.033	4.90	-42	-63	-39
		0.033	4.90	-33	-63	-42
0.000	137	0.000	6.11	-57	-42	21 L STG/IPL
		0.000	5.71	-57	-27	21 L supramarginal gyrus
		0.003	5.34	-57	-45	3 L MTG
0.002	32	0.000	6.11	-12	27	3 Corpus callosum
0.001	36	0.001	5.56	15	42	-18 R orbital SFG
0.000	55	0.004	5.29	-18	60	-9 BA11
0.000	59	0.010	5.13	0	45	-18 L rectus
		0.037	4.88	-3	54	-24
0.008	23	0.015	5.05	-6	-3	63 L SMA
0.007	24	0.019	5.01	-30	27	3 L insula

Functional FAS in Conversion Disorder						
0.016	19	0.024	4.96	-3	-39	-51 L brainstem
0.016	19	0.029	4.92	9	9	48 R SMA
0.007	24	0.030	4.92	-42	-33	-18 L ITG

Legend: ¹LCT corresponds in this case to the repetition of “pa-ta-ka” or “ta-ta-ta” synchronized with a visual stimulus; LCT = long click train, three times “pa-ta-ka” or “ta-ta-ta”; NCT = no click train, only the preparatory cue; SMA = supplementary motor area; R = right; L = left; SMC = sensorimotor cortex; IFG = inferior frontal gyrus; STG = superior temporal gyrus; CB = cerebellum; MFG = middle frontal gyrus; MTG = middle temporal gyrus.

3. Discussion

We described a patient who experienced transient psychotic symptoms after a fall down the staircase and developed a FAS. Repeated neurological and neuroradiological investigations formally ruled out damage to the central nervous system (CNS). Moreover, an fMRI experiment demonstrated normal activations of the speech network during a syllable repetition task. Stress could rapidly trigger an accent change, language mixing and switching, and speech could turn into an incomprehensible phonological jargon. Neurocognitive deficits were attested and remained quite stable over the period of 1,5 years. However, remarkably, performance on the naming task (BNT) regressed quite spectacularly, and inexplicably, during this time.

The onset of FAS after a traumatic experience has been previously reported in Verhoeven et al. (13), where the patient was nearly involved in a car accident as a cyclist and developed FAS after this experience. In Keulen et al. (45), the patient was hit by a

Functional FAS in Conversion Disorder

car as a pedestrian, but did not suffer any structural CNS damage. A few months later, an abrupt change of personality is described. This led to the patient being fired from her job, after which a foreign accent suddenly arose. In Reddy et al. (46), the patient suddenly developed FAS after suffering from a (second) divorce. Antecedents of depression and suicidal ideation were present.

Language mixing and switching

Although a few FAS patients have been reported with pathological language mixing and/or switching, jargon seems to be a relatively new element in the clinical presentation of FAS. In 2001, Reeves and Norton (14, see also Reeves et al. (15)) reported a 65-year-old schizophrenic patient who presented with FAS concomitant with psychotic exacerbations after withdrawal from medication. The disordered speech in schizophrenia was accounted for as a disturbance of inhibition mechanisms in relation to defective prefrontal neurotransmitter circuitry with associated executive dysfunctions (47). This balance was restored by administering dopaminergic drugs. The clearest example, however, of language mixing and switching in the FAS literature is the 51-year-old female Dutch patient described by Verhoeven et al. (13), also mentioned above. Her Dutch pronunciation was characterized by a French accent and her language showed syntactic and morphological features of French. In addition, she occasionally used French words or expressions. Importantly, the patient was a teacher of French as a second language. This familiarity with the accent and the lexical and grammatical characteristics of second language learners clearly distinguishes their patient from the current one.

The (phonological) jargon demonstrated by current patient has previously been associated with psychosis and psychopathy (48, 49). Most interestingly, FAS here could

Functional FAS in Conversion Disorder

be triggered by conscious manipulation of the subject of conversation. It is not the first time that a link between conversationally related stressors and FAS has been attested. In Keulen et al. (50) the foreign-sounding accent of their native French-speaking patient disappeared when an emotional subject was introduced. Sudden resolution related to emotionally laden content has previously been argued to indicate psychogenic etiology (51).

Stress, dopamine, FAS and jargon...

In order to explain the fluctuations in the accent and the evolution towards jargon speech, it seems essential to evaluate what the effects of (emotional) stress on speech can be. Hansen and Patil argue that “[...] stress is a psychological state that is a response to a perceived threat or task demand and is normally accompanied by specific emotions (e.g., fear, anger, anxiety, etc). These changes can affect speech behavior, even against an individual’s will.” (52, p. 109). How and whether stress causes (significant) impact on physical and/or psychological health depends a lot on an individual’s resilience (53). Current patient repeatedly admitted her accent changed as a result of the presence of an increased number of stimuli, which she could not handle.

Interestingly, stress interferes with dopamine regulation: increased stress raises dopamine levels in the brain. Dopamine modulates prefrontal cortex inputs to the amygdala, and via the amygdala, to the hippocampus. This is one reason why elevated stress affects (esp. non-emotional) memory functioning: it has been shown in animals that stress causes structural changes in the hippocampus, e.g. via glutamate blockage (54) which causes long-term depression of synapses situated in this region, as well as

Functional FAS in Conversion Disorder
impairing their long-term potentiation (55). In this respect it is interesting to note that patient demonstrated deficits with respect to memory and executive functioning.

The hypothesis of a dopamine dysregulation in FAS patients has also been raised in the context of hallucinations in schizophrenic and bipolar patients (15, 56). The case described by Reeves et al. (14, see also Reeves et al. (15)) switched language register and underwent an accent change in association with exacerbations, which were controlled after a pharmacological treatment including the dopamine antagonist olanzapine (20 mg).

Current patient did not suffer schizophrenia, and psychotic symptoms were only mentioned as fleeting symptoms in the history; but could no longer be corroborated in psychodiagnostic testing. The (fluctuating) accent change in relation to a self-perceived increase of stress(ors) in this patient may have caused subtle changes in neurotransmitter regulation that led to symptoms that were reminiscent of these functional FAS cases.

Still, it seems clinical experience, combined with thorough analysis of a patient's antecedents, cognitive profile, psychiatric characteristics and behavioral abnormalities is still often judged insufficient to support the hypothesis of a psychogenic or functional origin. Nevertheless, the available psychodiagnostic tests often lack the power to allow for an unequivocal diagnosis. For many FAS cases a formal diagnosis as “functional” has proven problematic. Lee et al. identified several characteristics that help to distinguish functional and structural FAS cases (57). These include previous motor disturbances causing the maladaptive speech response, inconsistencies in accent production, the adoption of unusual mannerisms in speech, and the speech disturbances being transient and reversible. In this case, one can wonder whether motor disturbance led to the fall from the stairs after which the foreign accent syndrome developed. All the other characteristics were present in this case. In the literature, foreign accent syndrome has

Functional FAS in Conversion Disorder
already been classified as, or in conjunction with conversion disorder, on several occasions (13, 58, 59).

The relation between conversion disorder and functional foreign accent syndrome definitely warrants further exploration in research. The effects and possibilities for treatment also necessitate more in-depth studies. In this respect, for current patient, it is especially noteworthy that a large-scale epidemiological study has shown that childhood trauma does have a negative impact on conversion disorder therapy outcome (60) and it was mentioned earlier that patient claimed to not have benefited significantly from previous therapy. In a very recent paper by Birdsey and Millar (61), CBT was also proposed to a woman suffering FAS on a psychogenic basis. Although CBT in that case study helped to reduce distress caused by the disorder as it did for this patient, it was not reported CBT helped to diminish the FAS and associated accent change itself.

4. Conclusion

A case of FAS is described in which jargon speech was observed. Although an underlying mental disorder, such as schizophrenia, was not formally objectified by psychodiagnostic tests, the atypical dissociations within the neurolinguistic manifestations strongly indicated a functional etiology, such as conversion disorder. Fluctuations of the speech symptoms can be induced by manipulating stressors. It is concluded that the neurolinguistic profile, symptom evolution and fMRI results are not suggestive of a neurological disorder, but rather with a functional FAS.

Author contributions

Manuscript drafting: SK, PM, JV, CVDF-C, LDV, LDP, TD; Neuropsychological and

Functional FAS in Conversion Disorder
neurolinguistics exams: SK, PM, LDV, LDP, TD; fMRI study: SK, PM, RB, KVD, PVS,
HR, JDM, FVO; Manuscript editing: all authors. Manuscript revision: SK, LDV, CVD-
C.

Funding sources

This study was funded by the research council of the Vrije Universiteit Brussel and University of Groningen under project code OZR BOF2545.

Stefanie Keulen is now a Postdoctoral Fellow of the Research Foundation - Flanders (FWO)

Ethical considerations

Ethical approval was obtained from the Ethics Committee for the Social Sciences and Humanities of Antwerp University, Belgium, SHW_18_26, CME Vrije Universiteit Brussel, study number 2016-135, and GGZ Breburg, Tilburg, The Netherlands.

Conflict of interest

The authors have no conflict of interest to declare.

References

1. Redlinger WE, Park TZ. Language mixing in young bilinguals. J Child Lang. 1980 Jun;7(2):337-52.

2. Meisel JM. Early differentiation of languages in bilingual children. In: L Wei. Bilingualism across the lifespan: Aspects of acquisition, maturity and loss. London: Routledge; 2000. p. 13-40.
3. Duran, L. Toward a better understanding of code switching and interlanguage in bilinguality: Implications for bilingual instruction. *The journal of educational issues of language minority students*. 1994; 14: 69-88.
4. Abutalebi J, Green D. Bilingual language production: The neurocognition of language representation and control. *J Neuroling*. 2007;20:242-75
5. Perani D, Abutalebi J. Neural basis of first and second language processing. *Curr Opin Neurobiol*. 2005 Apr;15(2):202-6.
6. Hernandez A. Language switching in the bilingual brain: What's next? *Brain Lang*. 2009 May-Jun;109(2-3):133-140.
7. Abutalebi J, Miozzo A, Cappa SF. Do subcortical structures control 'language selection' in polyglots? Evidence from pathological language mixing. *Neurocase*. 2008;6(1):51-6.
8. Mariën P, Abutalebi J, Engelborghs S, De Deyn PP. Pathological of language switching and mixing in an early bilingual child with subcortical aphasia. *Neurocase*. 2005 Dec;11(5):385-98.
9. Ansaldo AI, Saidi LG, Ruiz A. Model-driven intervention in bilingual aphasia: Evidence from a case of pathological language mixing. *Aphasiology*. 2010;24(2):309-24.
10. Aglioti S, Fabbro F. Paradoxical selective recovery in a bilingual aphasic following subcortical lesion. *NeuroReport*. 1993 Sep;4(12):1359-62.
11. Fabbro F, Skrap M, Aglioti S. Pathological switching between languages after frontal lesions in a bilingual patient. *J of Neurol Neurosurg Psychiatry*. 2000;68(5):650-52.

12. Hernandez AE, Dapretto M, Mazziotta J, Bookheimer, S. Language switching and language representation in Spanish–English bilinguals: An fMRI study. *NeuroImage*. 2001 Aug;14(2):510-20.
13. Verhoeven J, Mariën P, Engelborghs S, D’Haenen H, De Deyn PP. (2005). A foreign speech accent in a case of conversion disorder. *Behav Neurol*. 2005;16(4): 225-32.
14. Reeves RR, Norton JW. Foreign accent-like syndrome during psychotic exacerbations. *Neuropsychiatry Neuropsychol Behav Neurol*. 2001;14(2):135–38.
15. Reeves RR, Burke RS, Parker JD. Characteristics of psychotic patients with foreign accent syndrome. *J Neuropsychiatry Clin Neurosci*. 2007;19(1):70–6.
16. Gurnani A, Horwitz J. Adult Woman Presenting with Foreign Accent Syndrome (FAS): A Case Study. *Arch Clin Neuropsychology*. 2017;32(6): 667– 765.
17. Hillis AE, Boatman D, Hart J, Gordon B. (1999). Making sense out of jargon A neurolinguistic and computational account of jargon aphasia. *Neurology*. 1999; Nov 10;53(8):1813-24
18. Rohrer JD, Rossor MN, Warren JD. Neologistic jargon aphasia and agraphia in primary progressive aphasia. *J Neurol Sci*, 2009;277: 155-9.
19. Marshall J, Robson J, Pring T, Chiat S. Why does monitoring fail in jargon aphasia? Comprehension, judgment, and therapy evidence. *Brain Lang*. 1998;63(1): 79-107.
20. Paradis M. Bilingualism and neuropsychiatric disorders. *J Neuroling*. 2008 May;21(3):199-230.
21. Walen SR. Phrenophobia, *Cognit Ther Res*. 1982;6(4): 399-408.
22. Kaplan E, Goodglass H, Weintraub S. Boston Naming Test. Philadelphia: Lee & Febiger; 1983.

23. Visch-Brink EG, Vandenborre D, De Smet HY, Mariën P. Comprehensive Aphasia Test - Nederlands (CAT-NL). Amsterdam: Pearson; 2014.
24. Randolph C, Tierney MC, Mohr E, Chase TN. (1998). The repeatable battery for the assessment of neuropsychological status (RBANS): preliminary clinical validity. J Clin Exp Neuropsychol. 1998;20(3):310-19.
25. Rey A. L'examen clinique en psychologie. Paris: Presses Universitaires de France ; 1964.
26. Reitan R. Validity of the Trail Making test as an indicator of organic brain damage. Percept Mot Skills. 1958;8:271-76.
27. Tombaugh TN. The Test of Memory Malinger. San Antonio, TX: Pearson Clinical; 1996.
28. Kooij A, Dek J. Wechsler Adult Intelligence Scale IV – Dutch version. Amsterdam: Pearson; 2012.
29. Heaton RK, Chelune GJ, Talley JL, Kay GC, Curtiss G. Wisconsin card sorting test. Odessa, FL: Manual Psychological Assessment Resources; 1993.
30. Wechsler D. Wechsler memory scale – revised: manual. New York, NY: The Psychological Corporation; 1987.
31. Brickenkamp R. Aufmerksamkeits-Belastungs-Test (Test d2). 1. Auflage. Göttingen: Hogrefe; 1962.
32. Butcher JN, Dahlstrom WG, Graham JR, Tellegen AM, Kaemmer B. Minnesota Multiphasic Personality Inventory-2 (MMPI-2): Manual for administration and scoring. Minneapolis, MN: University of Minnesota Press; 1989.
33. Costa PT, McCrae RR. The NEO-PI/NEO-FFI manual supplement. Odessa, FL.: Psychological Assessment Resources ; 1989.
34. Thygesen KL, Drapeau M, Trijsburg RW, Lecours S, de Roten Y. (2008). Assessing defense styles: Factor structure and psychometric properties of the new Defense

- Functional FAS in Conversion Disorder
Style Questionnaire 60 (DSQ-60). *Rev Int Psicol Ter Psicol.* 2008;8(2):171-181.
35. Cima M, Merckelbach H, Hollnack S, Butt C, Kremer K, Schellbach-Matties R, et al. (2003). The Other Side of Malingering: Supernormality. *Arch Clin Neuropsychol.* 2003;17(2):235–243.
 36. Beck AT, Steer RA & Brown GK. Manual for the Beck Depression Inventory-II. San Antonio, TX: Psychological Corporation; 1996.
 37. Desmet M, Vanheule S, Groenvynck H, Verhaeghe P, Vogel J, & Bogaerts S. (2007). The depressive experiences questionnaire. *Eur J Psychol Assess.* 2007;23:89-98.
 38. Merten T, Stevens A. List of Indiscriminate Psychopathology (LIPP). Berlin/Tuebingen: unpublished manuscript; 2012.
 39. Rotter JB, Lah MI, Rafferty JE. The Rotter Incomplete Sentences Blank, second edition manual. New York, NY: Psychological Corporation; 1992.
 40. Kernberg OF. Severe personality disorders: Psychotherapeutic strategies. Yale University Press; 1993.
 41. Friedman AF, Levak RW, Nichols DS, Webb JT. Psychological assessment with the MMPI-2. London: Routledge; 2014.
 42. American Psychiatric Association. Diagnostic and statistical manual of mental disorders. 5th ed. Arlington, VA; 2013.
 43. Verhoeven J, Hageman G. De verstemlozing van frictieven in Vlaanderen, *Nederlandse Taalkunde.* 2007;12(2):139-152.
 44. Brendel B, Hertrich I, Erb M, Lindner A, Riecker A, Grodd W, Ackermann H. The contribution of mesiofrontal cortex to the preparation and execution of repetitive syllable productions: An fMRI study. *Neuroimage.* 2010;50(3):1219-30.
 45. Keulen S, Verhoeven J, De Page L, Jonkers R, Bastiaanse R, Mariën P. Psychogenic Foreign Accent Syndrome: A New Case. *Front Hum Neurosci.* 2016;10:1-13.

46. Reddy A, Shelton RC, Savage R, Birur B. Foreign Accent Syndrome presenting as Conversion Disorder: A rare presentation. *Journal of Nature and Science*. 2016; 2(7):197.
47. Barr WB, Bilder RM, Goldberg E, Kaplan E, Mukherjee S. The neuropsychology of schizophrenic speech. *J Commun Disord*. 1989; 22: 327-49.
48. Mazumdar PK, Chaturvedi SK, Sinha, VINOD, Gopinath PS. Scale for assessment of thought, language and communication in psychotic in-patients. *Psychopathology*. 1991;24(4):199-202.
49. Kitamura T, Okazaki Y, Fujinawa A, Yoshino M, Kasahara, Y. Symptoms of psychoses. A factor-analytic study. *Br J Psychiatry*. 1995;166(2):236-240.
50. Keulen S, Verhoeven J, Bastiaanse R, Mariën P, Jonkers R, Mavroudakakis N, Paquier P. Perceptual Accent Rating and Attribution in Psychogenic FAS: Some Further Evidence Challenging Whitaker's Operational Definition. *Front Hum Neurosci*. 2016;10:1-14.
51. Binder LM, Spector J, Youngjohn JR. (2012). Psychogenic Stuttering and Other Acquired Nonorganic Speech and Language Abnormalities, *Arch Clin Neuropsychol*. 2012;27(5):557-568.
52. Hansen JH, Patil S. Speech under stress: Analysis, modeling and recognition. In C; Müller, editor. *Speaker classification I*. Berlin, Heidelberg: Springer; 2007, p. 108-37.
53. Beasley M, Thompson T, Davidson J. Resilience in response to life stress: the effects of coping style and cognitive hardiness. *Pers Individ Differ*. 2003;34(1):77-95.
54. Yang CH, Huang CC, Hsu KS. (2005). Behavioral stress enhances hippocampal CA1 long-term depression through the blockade of the glutamate uptake. *J Neurosci*. 2005;25:4288-93.

55. Artola A, Von Frijtag JC, Fermont PC, Gispen WH, Schrama, LH, Kamal A, et al. Long-lasting modulation of the induction of LTD and LTP in rat hippocampal CA1 by behavioural stress and environmental enrichment. *Eur J Neurosci.* 2006;23(1). 261-272.
56. Moreno-Torres I, Berthier ML, del Mar Cid M, Green C, Gutiérrez A, García-Casares N, et al. Foreign accent syndrome: A multimodal evaluation in the search of neuroscience-driven treatments. *Neuropsychologia.* 2014;51(3):520–37.
57. Lee O, Ludwig L, Davenport R, Stone J. (2016). Functional foreign accent syndrome. *Prac Neurol.* 2016;16(5):409-11.
58. Tsuruga K, Kobayashi T, Hirai N, Kato S. Foreign Accent Syndrome in a Case of Dissociative (Conversion) Disorder. *Seishin Shinkeigaku Zasshi.* 2008;110:79-87.
59. Jones HN, Story TJ, Collins TA, DeJoy D, Edwards CL. Multidisciplinary assessment and diagnosis of conversion disorder in a patient with foreign accent syndrome. *Behav Neurol.* 2011;24(3):245–255.
60. Van der Feltz-Cornelis CM, Allen SF, Van Eck van der Sluijs J. Childhood sexual abuse predicts treatment outcome in conversion disorder/functional neurological disorder. An observational longitudinal study. *Brain Behav.* 2020;10.
61. Birdsey, N, Millar, JFA. Cognitive Behavioral Therapy for Foreign Accent Syndrome: A Single-Case Experimental Design. *Clinical Case Studies.* 2020, 1534650120936771.

Annex I: acquisition and analysis specifications for fMRI experiment (section 2.5)

A) Acquisition

Functional and structural MRI were conducted on a 3T GE scanner (Discovery MR750w) equipped with a standard 24-channel head coil. A BOLD sensitive T2*-weighted single shot spin echo (SE) planar imaging (EPI) sequence (TE/TR: 70/3000ms; FA: 90deg) was used resulting in voxel dimensions of 1.875 x 1.875 x 4 mm³ (interleaved) with 1mm gap, matrix = 128 x 128. Twenty-seven axial slices were acquired per volume, 200 volumes and 2 dummy scans per run. An additional SE-EPI sequence was obtained in the opposite left-right phase direction to be used as a fieldmap to correct the EPI-distortions. Three runs of 10min were used. In addition, an axial T1-weighted FSPGR BRAVO (176 slices) was taken to use for co-registration and normalization.

B) Analysis

Functional FAS in Conversion Disorder

fMRI data were unwarped using the top-up tool of fsl¹ and further analyzed using SPM12 software (www.fil.ion.ucl.ac.uk/spm). After slice timing and motion correction, the unwarped functional images were registered to the T1 weighted anatomical dataset. The anatomical image was then segmented and the forward deformation field was used to normalize the functional images to MNI (Montreal Neurological Institute) space. The registered functional data were smoothed spatially with a Gaussian kernel with a full width at half maximum (FWHM) of 6 x 6 x 6 mm³. Eight conditions (“pa-ta-ka” LC; “ta-ta-ta” LC; “pa-ta-ka” SC; “ta-ta-ta” SC; visual control LC+SC; “pa-ta-ka” NC; “ta-ta-ta” NC; instructions) were modeled as separate regressors and combined with the 6 movement regressors in the general linear model (GLM).

Similar to Brendel et al. (44), the general speech network was assessed by contrasting both LCs with the visual baseline condition. An initial uncorrected threshold of $p < 0.001$ at the voxel level was used to detect activations. Only clusters with more than 10 voxels were included in the table (see Table 2.2.). Activations were considered significant if the family-wise error (FWE) corrected p-value was smaller than 0.001 at the cluster level and smaller than 0.05 at the voxel level (see figure 1).

¹ Andersson JL, Skare S, Ashburner J. How to correct susceptibility distortions in spin-echo echo-planar images: application to diffusion tensor imaging. *Neuroimage*. 2003;20(2):870-888.